

# Unique Creeping Attachment after Autogenous Gingival Grafting: Case Report

(Migration post-opératoire unique du tissu gingival marginal suite à une greffe gingivale autogène : étude de cas)

- Francisco J. Otero-Cagide, DDS, Dip Perio •
- M. Fermín Otero-Cagide, DDS, Dip Perio •

## S o m m a i r e

*Cette étude de cas décrit une migration gingivale unique qui s'est produite suite à une greffe gingivale autogène. Cette migration s'est développée mésiobuccalement sur une récession large et profonde (3 mm) et s'est étendue le long de la récession buccale (2 mm) encore présente au niveau d'une première molaire supérieure recouverte d'une couronne complète en or. Cet article est le premier à être publié, dans la littérature dentaire, sur le recouvrement radiculaire complet d'une dent multiradiculaire restaurée suite à ce degré de migration gingivale.*

**Mots clés MeSH :** gingiva/physiology; gingiva/transplantation; wound healing

© J Can Dent Assoc 2003; 69(7):432-5  
Cet article a fait l'objet d'une révision par des pairs.

**A**utogenous gingival grafting or epithelialized free gingival grafting is a well-established pure mucogingival procedure for increasing the width of attached gingiva.<sup>1</sup> Since its introduction in 1963,<sup>2</sup> the procedure has proven reliable in increasing attached gingiva and stopping progressive gingival recession. Also, long-term stability (up to 4 years) of these treatment outcomes has been demonstrated.<sup>3</sup>

Although root coverage is not a primary goal of autogenous gingival grafting, it may occur, in cases of narrow recession (< 3 mm), as a result of bridging, whereby some of the grafted tissue remains vital over the avascular zone of the root.<sup>4</sup> Some root coverage may also result from another mechanism known as creeping attachment, which was described by Goldman and Cohen<sup>5</sup> as the postoperative migration of the gingival marginal tissue in a coronal direction over portions of a previously denuded root. Creeping attachment has been reported by several clinicians and is apparently best observed on mandibular anterior teeth with narrow recessions.<sup>6-8</sup> This phenomenon can be detected 1 to 12 months after graft surgery with an average coverage of about 1 mm.<sup>8</sup>

In 1982, Miller<sup>9</sup> proposed a modification of the conventional technique for autogenous gingival graft surgery for root coverage. This modification used a thicker graft (2 mm) positioned over a carefully planed root surface that had been previ-

ously conditioned with citric acid. With detailed suturing marginally and apically, the graft could be adapted in intimate contact with the recipient site. Later, Miller<sup>10</sup> presented a classification of recession defects based on the position of marginal tissue recession in relation to the mucogingival junction and the level of interproximal tissues (**Table 1**). With the modified technique proposed by Miller, root coverage is more predictable and more successful with Class I and II defects, whereas only partial coverage can be expected with Class III defects. Root coverage in Class IV defects should not be expected. Successful root coverage was found to depend mainly on bridging and partly on creeping.<sup>10</sup>

This case report describes a unique creeping attachment that developed mesiobuccally on a deep, wide recession (3 mm) and extended along the remaining buccal recession (2 mm) of a maxillary first molar with a full-crown gold restoration subsequent to autogenous gingival grafting. To the authors' knowledge, this degree of creeping attachment on a restored multiradical tooth has not previously been reported in the dental literature.

## Case Report

During a periodontal examination of a 45-year-old man at the Dental Clinic of the College of Dentistry, University of

Saskatchewan, in 1995, it was found that there was an inadequate band of gingiva on the facial aspect of the maxillary first and second molars, and the mesiobuccal root of the first molar had a recession of 3 mm apicocoronally and 3 mm mesiodistally. The remaining buccal aspect had 2 mm of recession. A full-crown gold restoration had been placed 6 years before. There was mild to moderate gingival inflammation marginally. The recession defect was classified as Class II mesiobuccally and Class I distobuccally (according to the Miller classification). There was no loss of interdental bone or soft tissue (Figs. 1a and 1b).

The patient's medical history was noncontributory, and he had no complaints or discomfort. Since appearance was not a concern, it was decided to treat the site by Miller's technique for autogenous gingival grafting to achieve root coverage, particularly for the mesiobuccal root of the first molar, and

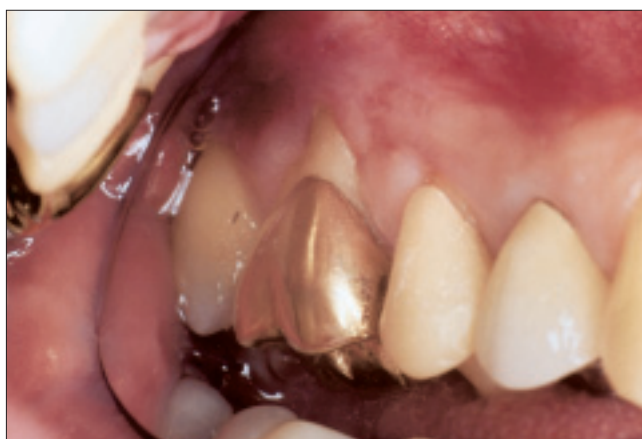also to increase the attached gingiva. As a full-crown restoration was planned for the second molar, it was recommended that the patient undergo autogenous gingival grafting of this tooth during the same surgical appointment, to increase the attached gingiva. The patient agreed to this treatment plan, and therapy was initiated with instructions for plaque control, followed by scaling and root planing.

### Surgical Procedure

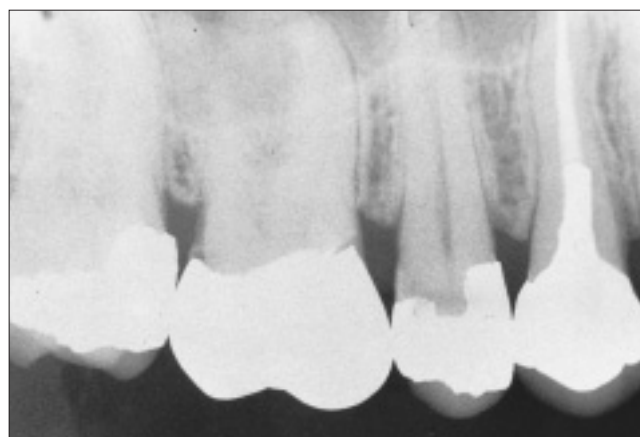During the surgical appointment, after local anesthesia had been achieved, the exposed root was planed thoroughly with a Gracey 7-8 curet, followed by burnishing a tetracycline hydrochloride solution (125 mg/mL) over the root with a cotton tip for 3 minutes. The area on the first molar that was to receive the gingival graft was prepared by creation of a partial-thickness flap according to Miller's techniques; the graft tissue (approximately 2 mm in thickness) was obtained from the palatal side at the level of the right premolars and first molar. The graft was sutured in place by means of interrupted sutures (5-0 polyglycolic acid sutures) at the coronal and apical corners. A basting-type of suture was also used, to obtain good adaptation of the graft to the recipient site. A conventional autogenous gingival graft (approximately 1 mm thick) was placed on the prepared recipient site of the second molar and was immobilized with cyanoacrylate. A non-eugenol periodontal dressing was applied to both donor and recipient sites. The patient received routine postsurgical instructions, including a 0.12% chlorhexidine mouth rinse twice daily along with 400 mg ibuprofen 4 times daily for 7 days. One week after the surgical procedure, the patient reported no major problems, although survival problems were evident for the graft over the mesiobuccal root of the first molar (Fig. 2). Healing of the grafted sites was assessed weekly for the first 3 weeks after surgery. At the 12-week evaluation there was a gain in attached gingiva around the first molar, but no root coverage had been achieved at the mesiobuccal root (Fig. 3). The patient had no complaints about the treatment

**Table 1** Classification of recession defects proposed by Miller<sup>10</sup>

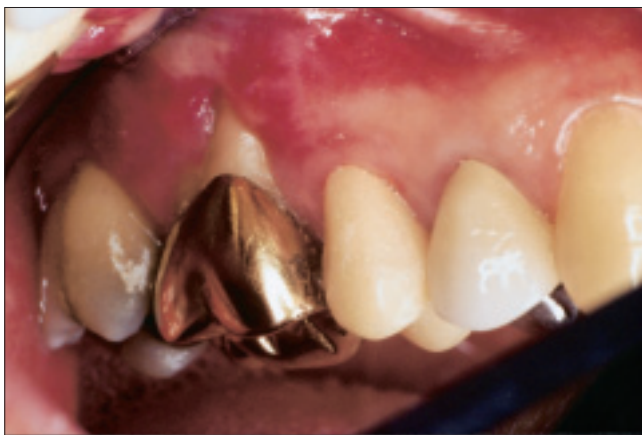
Class of defect	Description
I	Marginal tissue recession does not extend to mucogingival junction No loss of interdental bone or soft tissue
II	Marginal tissue recession extends to or beyond mucogingival junction No loss of interdental bone or soft tissue
III	Marginal tissue recession extends to or beyond mucogingival junction Loss of interdental bone or soft tissue occurs apical to the cemento-enamel junction, but coronal to apical extent of marginal tissue recession
IV	Marginal tissue recession extends beyond mucogingival junction Loss of interdental bone extends to level apical to extent of marginal tissue recession



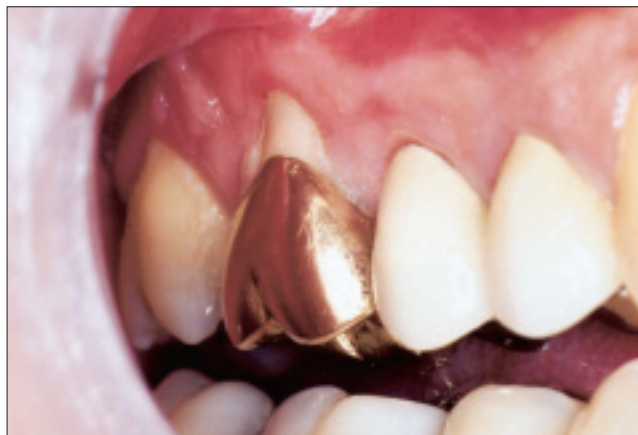**Figure 1a:** Preoperative view of the maxillary right first molar of a 45-year-old man shows a deep, wide recession mesiobuccally (3 mm), with inadequate attached gingiva. Distobuccal recession (2 mm) is also evident, but there is no loss of interdental soft tissue.



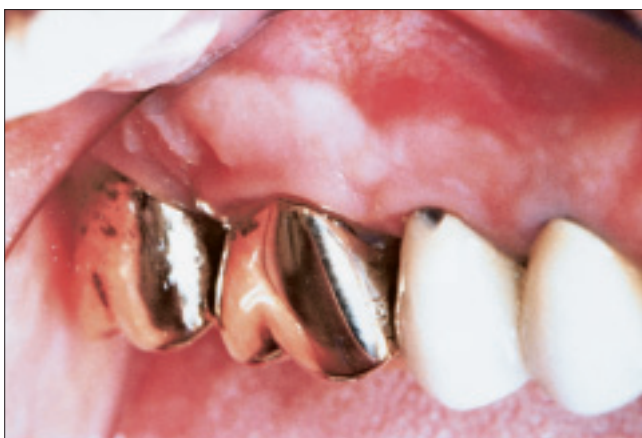**Figure 1b:** Preoperative radiographic view. There is no loss of interdental bone.



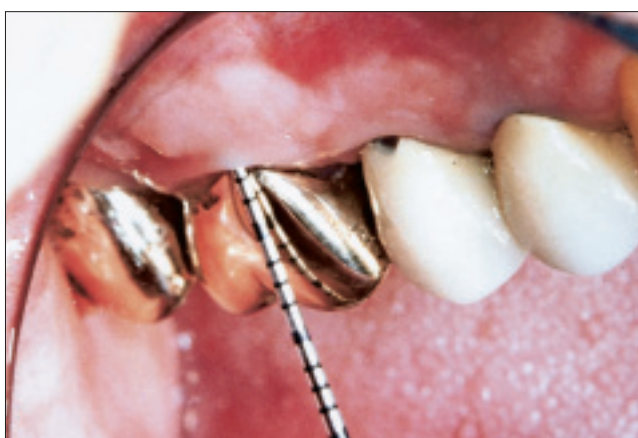**Figure 2:** Evaluation 1 week after surgery. A portion of the gingival graft overlying the mesiobuccal root suffered necrosis, and root coverage was not achieved.



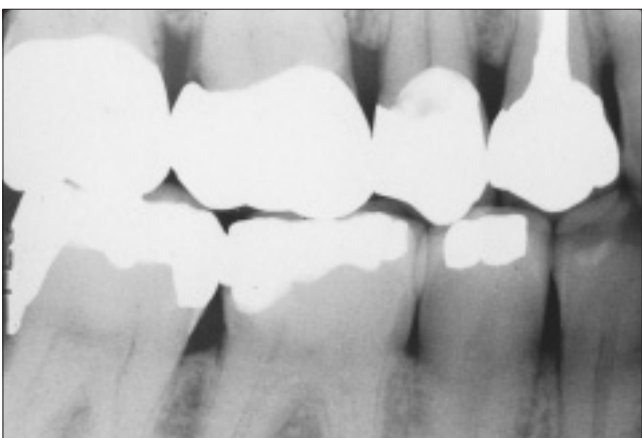
**Figure 3:** Appearance of the site 12 weeks after graft procedure. A gain in attached gingiva is evident, but root coverage of the mesiobuccal root was unsuccessful.



**Figure 4a:** Treated area 5 years after surgery. Impressive creeping attachment has resulted in complete root coverage.



**Figure 4b:** The gingiva exhibits resistance to probing and probing depth is minimal.



**Figure 4c:** Radiographic appearance of interproximal bone 5 years after surgery. Bone levels are good. A full-crown restoration has been placed on the second molar. The margins of the crown on the first molar were to be reassessed in the fixed prosthodontic clinic.

outcome, and oral hygiene was reinforced at this appointment. It was recommended that he proceed with his restorative plan and continue regular periodontal maintenance. He was seen at the periodontal clinic a couple of times for maintenance,

but no information was recorded about the grafted sites until 5 years after the surgery, when it was noticed that an impressive creeping attachment had developed, which entirely covered the previously denuded root of the first molar. The marginal tissue felt well attached and probing depth was minimal. A full-crown gold restoration had been placed over the second molar (Figs. 4a and 4b). The patient was referred back to the fixed prosthodontic clinic for assessment of the fractured porcelain at the margin of the crown on the second premolar and for reassessment of the margins of the crown on the first molar (Fig. 4c).

## Discussion

Only a few cases of creeping attachment after gingival grafting have been reported in the dental literature and these cases have usually involved unrestored mandibular anterior teeth in young adults.<sup>6-8</sup> Only one case has been reported in which bilateral creeping attachment resulted in root coverage of extensive, wide recessions on the maxillary cuspids after autogenous gingival grafting (in a 39-year-old patient).<sup>11</sup> Matter and Cimasoni<sup>6</sup> described 5 factors that seemed to have a definite influence on creeping attachment: width of the reces-



sion, position of the graft, interproximal bone resorption, position of the tooth and the patient's dental hygiene.

The degree of creeping attachment in the patient described here is unique, given the width and length of the recession defect, the tooth type, the presence of a restoration and the patient's age. It is difficult to explain the mechanism that could have caused the coronal migration of tissue, but bridging can be excluded because recession was still present 3 months after the procedure. Citric acid, as advocated by Miller, has been the agent most commonly used for root conditioning in root coverage procedures. A tetracycline hydrochloride solution has also been used.<sup>12,13</sup> Acid demineralization of the root surface is intended to facilitate formation of a new fibrous attachment, through exposure of collagen fibrils of the cementum or dentin, and to allow subsequent interdigitation of these fibrils with those in the covering connective tissue.<sup>14</sup> However, controlled studies have suggested that there is no clinical benefit of root conditioning with citric acid in conjunction with root coverage procedures.<sup>15,16</sup> The effect of conditioning the cementum surface with the tetracycline solution and its association with creeping attachment is unknown at this time. Furthermore, histological information to determine the type of attachment is not available.

Creeping attachment typically occurs within 1 to 12 months after the graft surgery.<sup>7</sup> However, creeping attachment may continue to progress beyond the first postoperative year. Even though it seems to occur whenever there has been an attempt to achieve root coverage with graft surgery, the amount of creeping attachment is unpredictable.<sup>17</sup> Therefore, a well-designed clinical trial, with careful observation of the clinical healing process of autogenous gingival grafts over the long term, is needed to identify factors that could play a significant role in this interesting clinical finding. Such studies might ultimately elucidate the mechanism of creeping attachment. ♦

---

*Le Dr F.J. Otero-Cagide est professeur agrégé de parodontie, Division de parodontie, Collège de médecine dentaire, Université de la Saskatchewan, Saskatoon (Saskatchewan).*

*Le Dr M.F. Otero-Cagide est professeur agrégé de parodontie, Département de parodontologie, Faculté de médecine dentaire, Université intercontinentale, Mexico.*

*Écrire au : Dr F.J. Otero-Cagide, Division de parodontologie, Collège de médecine dentaire, Université de la Saskatchewan, Saskatoon SK S7N 5E4. Courriel : otero@sask.usask.ca.*

*Les auteurs n'ont aucun intérêt financier déclaré.*

---

## Références

- Hall WB. Gingival augmentation/mucogingival surgery. In: Nevins M, Becker W, Kornman K, editors. Proceedings of the World Workshop in Clinical Periodontics; 1989 Jul 23–27; Princeton, New Jersey. Chicago: The American Academy of Periodontology; 1989. VII, p. 5–7.
- Björn H. Free transplantation of gingiva propia. *Sver Tandlak Tidskr* 1963; 22:684.
- Dorfman HS, Kennedy JE, Bird WC. Longitudinal evaluation of free autogenous gingival grafts. A four year report. *J Periodontol* 1982; 53(6):349–52.
- Sullivan HC, Atkins JH. The role of free gingival grafts in periodontal therapy. *Dent Clin North Am* 1969; 13(1):133–48.

- Goldman HM, Cohen DW. Periodontal therapy. 5th ed. St. Louis: C.V. Mosby Co.; 1973. p. 715–8.
- Matter J, Cimasoni G. Creeping attachment after free gingival grafts. *J Periodontol* 1976; 47(10):574–9.
- Matter J. Creeping attachment of free gingival grafts. A five-year follow-up study. *J Periodontol* 1980; 51(12):681–5.
- Bell LA, Valluzzo TA, Garnick JJ, Pennel BM. The presence of "creeping attachment" in human gingiva. *J Periodontol* 1978; 49(10):513–7.
- Miller PD Jr. Root coverage using a free soft tissue autograft following citric acid application. Part 1: Technique. *Int J Periodontics Restorative Dent* 1982; 2(1):65–70.
- Miller PD Jr. A classification of marginal tissue recession. *Int J Periodontics Restorative Dent* 1985; 5(2):9–13.
- Pollack RP. Bilateral creeping attachment using free mucosal grafts. A case report with 4-year follow-up. *J Periodontol* 1984; 55(11):670–2.
- Harris RJ. The connective tissue with partial thickness double pedicle graft: the results of 100 consecutively-treated defects. *J Periodontol* 1994; 65(5):448–61.
- Trombelli L, Schincaglia GP, Zangari F, Griselli A, Scabbia A, Calura G. Effects of tetracycline HCl conditioning and fibrin-fibronectin system application in the treatment of buccal gingival recession with guided tissue regeneration. *J Periodontol* 1995; 66(5):313–20.
- Polson AM, Proye MP. Effect of root surface alterations on periodontal healing. II. Citric acid treatment of the denuded root. *J Clin Periodontol* 1982; 9(6):441–54.
- Ibbott CG, Oles RD, Lavery WH. Effects of citric acid treatment on autogenous free graft coverage of localized recession. *J Periodontol* 1985; 56(11):662–5.
- Bouchard P, Etienne D, Ouhayoun JP, Nilvéus R. Subepithelial connective tissue grafts in the treatment of gingival recessions. A comparative study of 2 procedures. *J Periodontol* 1994; 65(10):929–36.
- Harris RJ. Creeping attachment associated with the connective tissue with partial-thickness double pedicle graft. *J Periodontol* 1997; 68(9):890–9.