

A Promising Periodontal Procedure for the Treatment of Adjacent Gingival Recession Defects

(Une procédure parodontale prometteuse pour le traitement de la récession gingivale)

• Tolga Fikret Tözüm, DDS, PhD •

S o m m a i r e

Divers rapports cliniques sur la reconstruction pour récession gingivale ont été publiés au cours de la dernière décennie. Plusieurs techniques ont été utilisées pour réaliser un recouvrement de la racine, notamment, l'application de greffes gingivales libres placées en volets latéraux ou semi-lunaires autour de la couronne, la régénération tissulaire guidée et la greffe de tissus conjonctifs. Cet article porte sur l'importance de la greffe des tissus conjonctifs, associée à une approche récente, connue sous le nom de procédure du tunnel, dans la gestion de la récession gingivale en une seule intervention. Cette procédure a été inaugurée en 1985 avec une conception en enveloppe et une greffe de tissus conjonctifs sous-épithéliaux pour une seule récession gingivale et elle est utilisée aujourd'hui pour couvrir des récessions gingivales adjacentes multiples. Une évaluation histologique de ces greffes de tissus conjonctifs démontre une régénération parodontale chez les sujets humains. Les essais cliniques ont donné de bons résultats, notamment, guérison rapide des tissus en raison d'un apport accru en sang, bons résultats esthétiques, excellente coopération de la part des patients et l'absence d'une deuxième chirurgie parodontale. Ces avantages soulignent le caractère approprié de cette technique qui améliore le taux de succès des greffes de tissus conjonctifs et augmente la superficie du recouvrement de la racine.

Mots clés MeSH : connective tissue/transplantation; gingival recession/surgery; gingivoplasty/methods

© J Can Dent Assoc 2003; 69(3):155-9
Cet article a fait l'objet d'une révision par des pairs.

Gingival recession is defined as the displacement of the gingival margin apical to the cemento-enamel junction.¹ It is characterized by the loss of periodontal connective tissue fibres, along with tooth cementum and alveolar bone.² The causes of gingival recession are periodontal disease, improper oral hygiene, frenal pull, bone dehiscence, improper restorations, tooth malposition, viral infections of the gingiva and subgingival calculus formation.³⁻¹⁷ Recession of the gingival tissue causes root hypersensitivity, poor esthetic appearance and cervical root caries.^{18,19} Gingival recession defects are typically treated by periodontal plastic surgery to correct or eliminate the deformities of the gingival mucosa.²⁰ Various mucogingival procedures have been used, including creation of free gingival grafts, laterally positioned flaps or semilunar coronally positioned flaps, as well as guided tissue regeneration (GTR) and connective tissue grafting.²¹⁻²⁶

Treatment of gingival recession defects with pedicle flaps results in a long junctional epithelial attachment.²⁷ Placement of a free gingival graft results in regeneration of cementum, bone and connective tissue attachment.²⁸ New bone and new cementum formation are observed with GTR.²⁹ However, in a recent review, Danesh-Meyer and Wikesjö³⁰ mentioned that GTR does not provide additional clinical benefits over connective tissue grafting or advanced flap procedures in the treatment of gingival recession. They proposed that the technical difficulties of GTR are more hazardous than helpful for the clinician in controlling primary wound closure, membrane exposure, space maintenance and unacceptable foreign-body reactions. Furthermore, performing connective tissue grafts over gingival recession defects results in periodontal regeneration.^{25,31-33}

Citric acid, fibronectin and tetracycline hydrochloride are commonly used for root conditioning to enhance root coverage and encourage a new connective tissue attachment

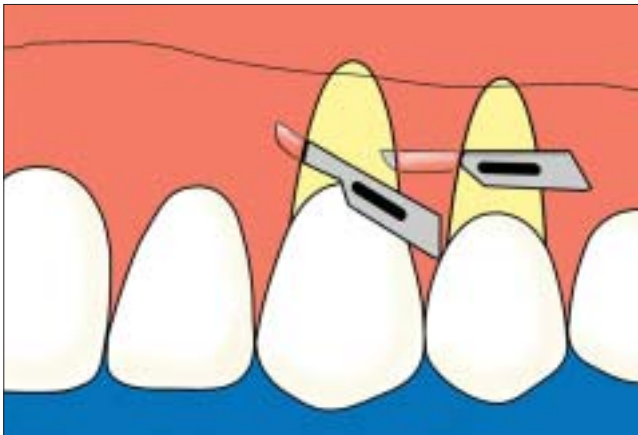


Figure 1: A partial-thickness dissection is performed by undermining the distal, mesial and interdental papillae.

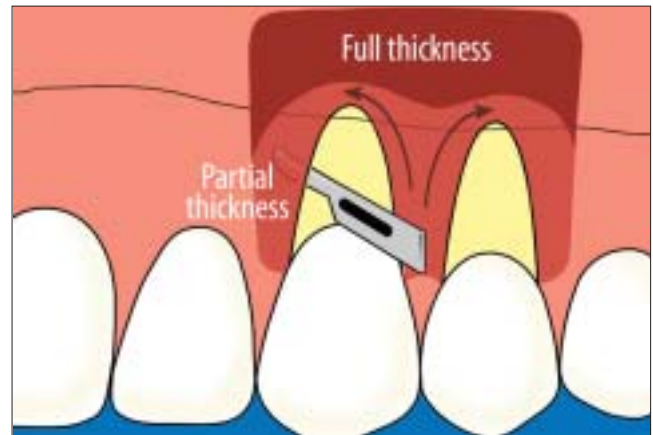


Figure 2: The partial-thickness flap is converted to a full-thickness flap in a coronoapical direction through the mucogingival junction (frontal view).

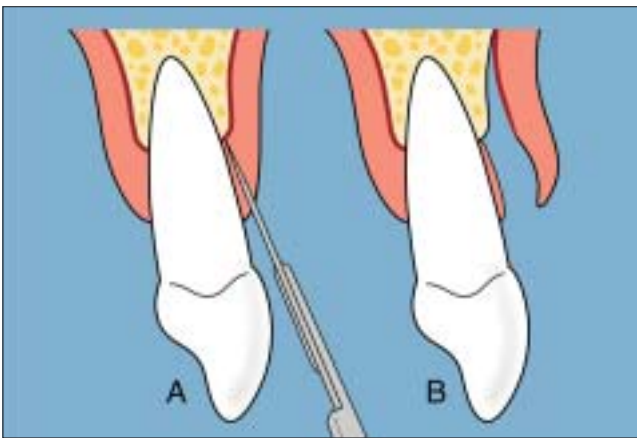


Figure 3: The partial-thickness flap is converted to a full-thickness flap (sagittal view).

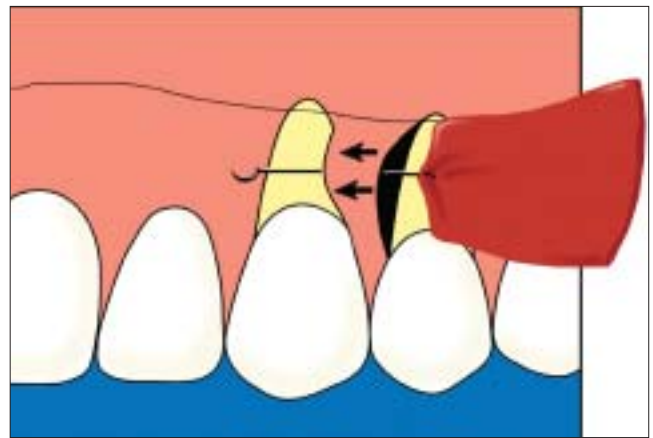


Figure 4: The connective tissue graft is introduced through the distal recession and passes through the tunnel.

between the root surface and the transplanted tissue.^{34–36} However, no significant benefits are reported with or without the application of these compounds.

This review focuses specifically on treatment of gingival recession defects with a recent procedure known as the tunnel procedure combined with connective tissue grafting. A MEDLINE search was performed to identify reports of this procedure in English publications appearing between 1985 and 2002. The aim of this article is to inform clinicians who are interested in new periodontal plastic surgical methods and to focus on a novel procedure that is highly successful in treating adjacent gingival recession defects.

Evaluation of Reports of Recipient Site Preparation by the Tunnel Procedure

Langer and Langer³⁷ described the subepithelial connective tissue grafting technique in 1985 for use in the treatment of adjacent gingival recession defects. The method involved root coverage by means of a partial-thickness dissection with 2 vertical releasing incisions. The authors reported satisfactory results in treating maxillary deep-wide recession defects,

including 4-year postoperative stability. The high success rate obtained with this type of graft was related to maintaining the blood supply at the overlying flap and the connective tissue basement. The major benefits of subepithelial connective tissue grafting are improved colour blending at the recipient site and reduced morbidity at the donor site.²⁰ In the same year, Raetzke³⁸ described the envelope technique for treatment of single deep-wide gingival recession defects; the method involved subepithelial connective tissue grafting in an envelope created around the root surface with a split-thickness dissection without vertical incisions. Preoperative measurements from 10 patients with 12 localized sites of recession ranged from 2.0 to 5.0 mm (mean 3.29) in depth and 1.5 to 6.0 mm (mean 3.63) in width. The postoperative results ranged from 0.0 to 2.0 mm (mean 0.67) and 0.0 to 4.0 mm (mean 1.46), respectively. In Raetzke's study, mean root coverage was 80%, and there was an average gain in keratinized gingiva of 3.5 mm. This technique offers many advantages, such as good healing (related to maximum contact between the graft and host tissues), minimal surgical trauma at the recipient area, increased blood supply from the lateral and papillary areas,

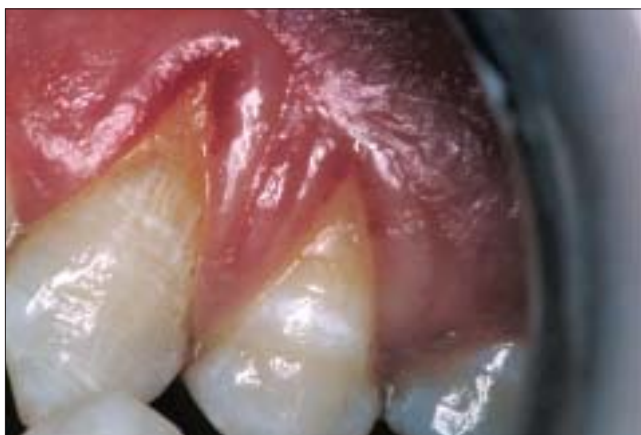

Figure 5a: Severe gingival recession defects are present on the maxillary canine and first premolar.

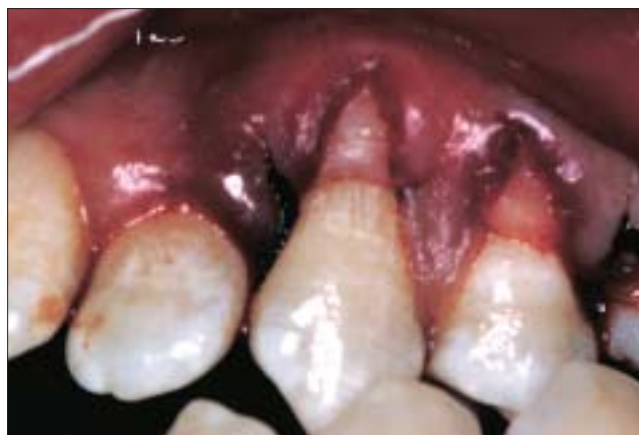

Figure 5b: Donor tissue is secured under the tunnel after the full-thickness dissection is performed.

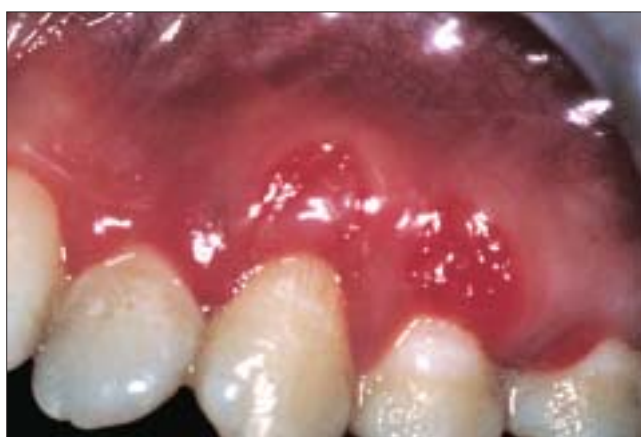

Figure 5c: At day 15 of healing, the treated defects show postoperative edema.

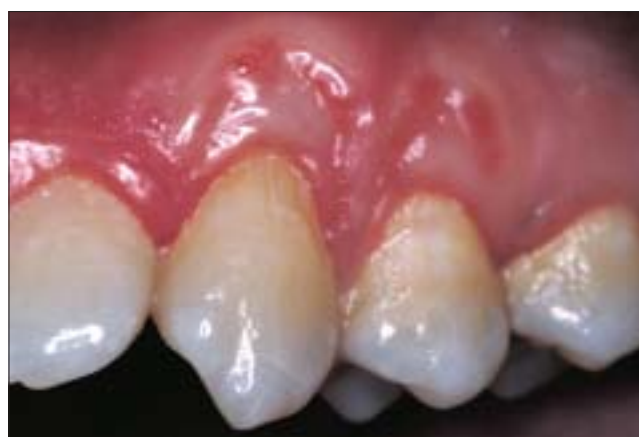

Figure 5d: The recipient site has acceptable contour and colour blending after 1 month of healing.

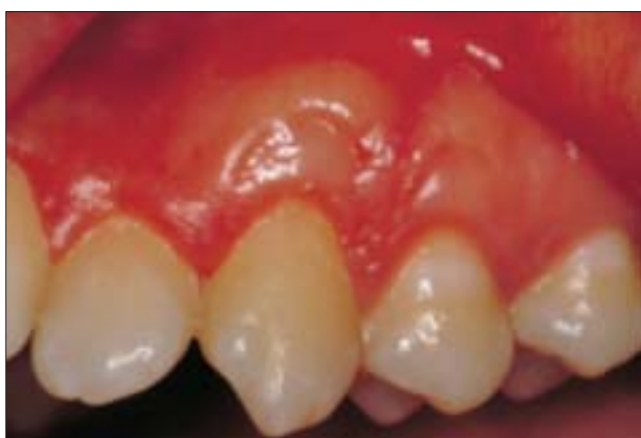

Figure 5e: Satisfactory root coverage has been attained after 8 months of healing.

minor wound surface at the palatal site and improved esthetic appearance in the early phase of healing.

In 1994 Allen^{33,39} demonstrated a supraperiosteal envelope technique in soft-tissue grafting for root coverage for multiple adjacent areas of gingival recession. He used partial-thickness dissection at the recipient area without vertical incisions. The

procedure was highly successful, and complete coverage was achieved in 14 (61%) of 23 sites. Five of the 9 remaining sites had 75% coverage, and 4 had coverage from 20% to 67%. The average root coverage for all sites was 84%. Allen also classified the results according to depth; complete coverage was achieved in 10 (83%) of 12 shallow defects and 4 (40%) of 10 moderate defects. Shallow defects averaged 95% coverage and moderate defects 73% coverage. The supraperiosteal envelope technique offers several advantages in the treatment of adjacent gingival recession defects. Surgical trauma at the recipient site is minimal, graft nutrition is augmented by lateral and papillary blood vessels, and, although the interdental papilla is dissected, the esthetic appearance of the surgical area is preserved through repositioning of the papilla with a single knot.³³

In 1999 Zabalegui and others⁴⁰ reported highly successful root coverage in the treatment of 21 teeth with subepithelial connective tissue grafting combined with a tunnel technique. They obtained 100% root coverage in 66.7% of the recession defects treated, with a mean coverage of 91.6% for all sites after 12 months. They suggested the same partial-thickness dissection procedure described by Allen^{33,39}; however, they

Table 1 Clinical studies performed to cover adjacent gingival recession defects with subepithelial connective tissue grafting and tunnel procedure

Reference	Flap design	Intermediate papilla	Mean root coverage (%)	Defect no.
Allen 1994	Partial-thickness dissection	Dissected	83	23
Zabalegui and others 1999	Partial-thickness dissection	Intact	91.6	21
Tözüm and Dini 2003	Partial thickness and full thickness	Intact	95	14

preferred to create a tunnel under the areas of gingival recession and to thus avoid dissecting the intermediate papilla of the adjacent recession defects. With this modification they reported early healing, high percentage of root coverage and improved esthetic results in multiple adjacent gingival recession defects. This procedure seems to be more predictable and demonstrates more satisfactory results than previously described techniques, which may be explained by the fact that less trauma is caused during preparation of the recipient site if the intermediate papillae remain intact.

Blanes and Allen⁴¹ introduced the bilateral pedicle flap-tunnel technique to cover adjacent recession defects with subepithelial connective tissue grafts. They modified the tunnel technique by incorporating a pedicle flap design and obtained 95% root coverage in 6 patients for at least 6 months. They suggested that this new combination offered many advantages, such as better adaptation and stability (because of the tunneled interproximal papilla), prevention of apical retraction and less surgical trauma. In 2001 Santarelli and others² published a case report describing use of a partial-thickness dissection with the tunnel approach and a single vertical incision for the treatment of maxillary central incisors. They introduced a subepithelial connective tissue graft into the tunnel through this single vertical incision, where the interdental papilla between adjacent teeth remained intact. They reported 100% root coverage after a year. In the same year Mahn⁴² presented another case involving the tunnel technique and an acellular dermal connective tissue allograft. He used full-thickness dissection with 2 vertical incisions to cover 3 adjacent gingival recession defects; successful coverage was obtained after 10 weeks. The interdental papillae were left intact.

Recently, Tözüm and Dini²⁵ used a modified tunnel procedure and subepithelial connective tissue grafting for the treatment of adjacent gingival recession defects. The recipient sites were prepared by partial-thickness dissection as described previously (Fig. 1).^{2,39,40} However, the partial-thickness dissection was converted to full thickness in the coronal direction through the mucogingival junction, to preserve more major gingival vessels inside the flap (Figs. 2-4).^{43,44} When compared with other tunnel procedures, the main challenge with this method is converting the partial-thickness flap to a full-thickness flap. The authors reported highly successful root coverage in 14 adjacent maxillary gingival recession

defects: average attachment gain of 3.67 mm, average root coverage of 3.28 mm and average reduction in pocket depth of 0.64 mm after 8 months. The mean root coverage was 95% (Figs. 5a-5e). This type of recipient-site preparation was described for periodontal flaps in 1977 by Mormann and Ciancio⁴³ for a human study in which fluorescein angiography was used. On the basis of their results, they proposed that the higher success rate of partial-thickness dissection was due to the full-thickness preparation in the apical area, where the major gingival blood supply was preserved. Preservation of the intermediate papilla and a minor modification during tunnel preparation in the coronal direction increased the nutrition of the graft from the lateral and papillary areas and, more important, from the apical direction.²⁵

Conclusions

The data reviewed here arise from clinical trials and case reports evaluating the efficiency of recipient-site preparation with the tunnel procedure and its modifications (Table 1). The success of root coverage seems to relate to the transplanted graft type and the procedure at the recipient site. It is clear that the flap design affects initial healing and the amount of coverage of the denuded roots during the follow-up period. The gingival blood supply should be preserved at the basement of the recipient site to increase initial healing and the success of the periodontal procedure.^{25,43,44} Preservation of the interdental papillae will reduce the trauma at the recipient site and improve early esthetic results. This new modification offers successful clinical results for both patients and clinicians. However, comparative long-term studies with larger sample sizes are necessary to fully understand the impact of the tunnel approach for the treatment of adjacent gingival recession defects. ♦

Remerciements : Les illustrations sont reprises, avec la permission de Quintessence International, de Tözüm TF, Dini FM. Treatment of adjacent gingival recessions with subepithelial connective tissue grafts and the modified tunnel technique. Quintessence Int 2003; 34(1):7-13.

Le Dr Tözüm est adjoint à la recherche au Département de parodontie, Faculté de médecine dentaire, Université Hacettepe, Ankara, Turquie.

Écrire au : Dr Tolga F. Tözüm, Département de parodontie, Faculté de médecine dentaire, Université Hacettepe, Sıhhiye - Ankara, Turquie. Courriel : ttozum@hacettepe.edu.tr

L'auteur n'a aucun intérêt financier déclaré.

Références

- Glossary of Periodontology Terms. American Academy of Periodontology. 4th ed. Chicago; 2001. p. 44.
- Santarelli GA, Ciancaglini R, Campanari F, Dinoi C, Ferraris S. Connective tissue grafting employing the tunnel technique: a case report of complete root coverage in the anterior maxilla. *Int J Periodontics Restorative Dent* 2001; 21(1):77-83.
- Contreras A, Slots J. Active cytomegalovirus infection in human periodontitis. *Oral Microbiol Immunol* 1998; 13(4):225-30.
- Lõe H, Anerud A, Boysen H. The natural history of periodontal disease in man: prevalence, severity and extent of gingival recession. *J Periodontol* 1992; 63(6):489-95.
- Serino G, Wennstrom JL, Lindhe J, Eneroth L. The prevalence and distribution of gingival recession in subjects with a high standard of oral hygiene. *J Clin Periodontol* 1994; 21(1):57-63.
- Tözüm TF, Berker E, Ersoy F, Tezcan I, Sanal Ö. The relationship between periodontal status and peripheral levels of neutrophils in two consanguineous siblings with severe congenital neutropenia: case reports. *Quintessence Int* 2003; 34(3):221-6.
- Goldstein M, Nasatzky E, Goultzschin J, Boyan BD, Schwartz Z. Coverage of previously carious roots is as predictable a procedure as coverage of intact roots. *J Periodontol* 2002; 73(12):1419-26.
- Trott JR, Love B. An analysis of localized recession in 766 Winnipeg High School students. *Dent Pract Dent Res* 1966; 16(6):209-13.
- Lost C. Depth of alveolar bone dehiscences in relation to gingival recessions. *J Clin Periodontol* 1984; 11(9):583-9.
- Donaldson D. Gingival recession associated with temporary crowns. *J Periodontol* 1973; 44(11):691-6.
- Lindhe J, Socransky SS, Nyman S, Westfelt E. Dimensional alteration of the periodontal tissues following therapy. *Int J Periodontics Restorative Dent* 1987; 7(2):9-21.
- Peacock ME, Mott DA, Cuenin MF, Hokett SD, Fowler EB. Periodontal plastic surgical technique for gingival fenestration closure. *Gen Dent* 2001; 49(4):393-5.
- Sangnes G, Gjermo P. Prevalence of oral soft and hard tissue lesions related to mechanical toothcleaning procedures. *Community Dent Oral Epidemiol* 1976; 4(2):77-83.
- Wilson RD. Marginal tissue recession in general dental practice: a preliminary study. *Int J Periodontics Restorative Dent* 1983; 3(1):40-53.
- Agudio G, Pini Prato G, Cortellini P, Parma S. Gingival lesions caused by improper oral hygiene measures. *Int J Periodontics Restorative Dent* 1987; 7(1):52-65.
- Pini Prato G. Mucogingival deformities. *Ann Periodontol* 1999; 4(1):98-101.
- Blue AH. Periodontal plastic procedures in esthetic dentistry. *Tex Dent J* 2001; 118(10):972-6.
- Pini Prato G, Clauser C, Tonetti MS, Cortellini P. Guided tissue regeneration in gingival recessions. *Periodontol 2000* 1996; 11:49-57.
- Anson D. Periodontal esthetics and soft-tissue root coverage for treatment of cervical root caries. *Compend Contin Educ Dent* 1999; 20(11):1043-46,1048-50,1052.
- Miller PD Jr. Root coverage grafting for regeneration and aesthetics. *Periodontol 2000* 1993; 1:118-27.
- Miller PD Jr. Root coverage using the free soft tissue autograft following citric acid application. III. A successful and predictable procedure in areas of deep-wide recession. *Int J Periodontics Restorative Dent* 1985; 5(2):14-37.
- de Waal H, Kon S, Ruben MP. The laterally positioned flap. *Dent Clin North Am* 1988; 32(2):267-85.
- Thompson BK, Meyer R, Singh GB, Mitchell W. Desensitization of exposed root surfaces using a semilunar coronally positioned flap. *Gen Dent* 2000; 48(1):68-71.
- Pini Prato G, Clauser C, Cortellini P, Tinti C, Vincenzi G, Pagliaro U. Guided tissue regeneration versus mucogingival surgery in the treatment of human buccal recessions. A 4-year follow-up study. *J Periodontol* 1996; 67(11):1216-23.
- Tözüm TF, Dini FM. Treatment of adjacent gingival recessions with subepithelial connective tissue grafts and the modified tunnel technique. *Quintessence Int* 2003; 34(1):7-13.
- Wang HL, Kimble K, Eber R. Use of bone grafts for the enhancement of a GTR-based root coverage procedure: a pilot case study. *Int J Periodontics Restorative Dent* 2002; 22(2):119-27.
- Caffesse RG, Kon S, Castelli WA, Nasjleti CE. Revascularization following the lateral sliding flap procedure. *J Periodontol* 1984; 55(6):352-8.
- Pasquinelli KL. The histology of new attachment utilizing a thick autogenous soft tissue graft in an area of deep recession: a case report. *Int J Periodontics Restorative Dent* 1995; 15(3):248-57.
- Cortellini P, Clauser C, Pini Prato GP. Histologic assessment of new attachment following the treatment of a human buccal recession by means of guided tissue regeneration procedure. *J Periodontol* 1993; 64(5):387-91.
- Danesh-Meyer MJ, Wikesjö UM. Gingival recession defects and guided tissue regeneration: a review. *J Periodontol Res* 2001; 36(6):341-54.
- Harris RJ. Successful root coverage: a human histologic evaluation of a case. *Int J Periodontics Restorative Dent* 1999; 19(5):439-47.
- Bruno JF, Bowers GM. Histology of a human biopsy section following the placement of a subepithelial connective tissue graft. *Int J Periodontics Restorative Dent* 2000; 20(3):225-31.
- Allen AL. Use of the supraperiosteal envelope in soft tissue grafting for root coverage. II. Clinical results. *Int J Periodontics Restorative Dent* 1994; 14(4):302-15.
- Bouchard P, Nilveus R, Etienne D. Clinical evaluation of tetracycline HCl conditioning in the treatment of gingival recessions. A comparative study. *J Periodontol* 1997; 68(3):262-9.
- Cortellini P, DeSanctis M, Pini Prato G, Baldi C, Clauser C. Guided tissue regeneration procedure using a fibrin-fibronectin system in surgically induced recession in dogs. *Int J Periodontics Restorative Dent* 1991; 11(2):150-63.
- Harris RJ. The connective tissue with partial thickness double pedicle graft: the results of 100 consecutively-treated defects. *J Periodontol* 1994; 65(5):448-61.
- Langer B, Langer L. Subepithelial connective tissue graft technique for root coverage. *J Periodontol* 1985; 56(12):715-20.
- Raetzke PB. Covering localized areas of root exposure employing the "envelope" technique. *J Periodontol* 1985; 56(7):397-402.
- Allen AL. Use of the supraperiosteal envelope in soft tissue grafting for root coverage. I. Rationale and technique. *Int J Periodontics Restorative Dent* 1994; 14(3):216-27.
- Zabalegui I, Sicilia A, Cambra J, Gil J, Sanz M. Treatment of multiple adjacent gingival recessions with the tunnel subepithelial connective tissue graft: a clinical report. *Int J Periodontics Restorative Dent* 1999; 19(2):199-206.
- Blanes RJ, Allen EP. The bilateral pedicle flap-tunnel technique: a new approach to cover connective tissue grafts. *Int J Periodontics Restorative Dent* 1999; 19(5):471-9.
- Mahn DH. Treatment of gingival recession with a modified "tunnel" technique and an acellular dermal connective tissue allograft. *Pract Proced Aesthet Dent* 2001; 13(1):69-74.
- Mormann W, Ciancio SG. Blood supply of human gingiva following periodontal surgery. A fluorescein angiographic study. *J Periodontol* 1977; 48(11):681-92.
- Mormann W, Meier C, Firestone A. Gingival blood circulation after experimental wounds in man. *J Clin Periodontol* 1979; 6(6):417-24.