

# Treatment and Long-term Follow-up of a Patient with Hereditary Gingival Fibromatosis: A Case Report

(Traitement et suivi à long terme d'une patiente souffrant de fibromatose gingivale héréditaire : étude de cas)

- Anastasia Kelekis-Cholakis, BA, DMD, Dip Perio •
- William A. Wiltshire, BChD (Hons), M Dent, MChD (Orth), DSc •
- Catalena Birek, DDS, PhD, Dip Oral Pathol •

## S o m m a i r e

*Cette étude de cas traite de la complexité du diagnostic buccal, du traitement et du suivi à long terme de la forme héréditaire de la fibromatose gingivale à répétition et porte sur une jeune fille de 13 ans souffrant d'une hyperplasie gingivale évolutive à répétition, qui a nécessité des traitements parodontaux et orthodontiques consécutifs. La première série de traitements a consisté en une gingivectomie à biseau inversé, qui a été pratiquée dans les 4 quadrants et a été suivie d'un traitement orthodontique. L'analyse microscopique des échantillons prélevés par gingivectomie a corroboré le diagnostic clinique. Trois ans plus tard, l'hyperplasie est réapparue dans les 4 quadrants. Pour faciliter le mouvement orthodontique des dents et assurer une esthétique optimale, une autre gingivectomie a été pratiquée dans l'ensemble de la bouche. Un an plus tard, aucun signe de récurrence n'était observé. Chez les patients souffrant de cette affection, il est recommandé d'assurer un suivi rigoureux après une gingivectomie, afin de procéder aux traitements localisés qui s'imposent, s'il y a lieu.*

**Mots clés MeSH :** case report; fibromatosis, gingival/pathology; fibromatosis, gingival/therapy

© J Can Dent Assoc 2002; 68(5):290-4  
Cet article a fait l'objet d'une révision par des pairs.

**H**ereditary gingival fibromatosis, also known as elephantiasis gingivae, hereditary gingival hyperplasia, idiopathic fibromatosis and hypertrophied gingivae, is a rare (1 in 750,000) hereditary condition characterized by slow, progressive enlargement of the gingivae.<sup>1</sup> The mode of inheritance is believed to be autosomal dominant,<sup>2</sup> although reports of a recessive mode of inheritance have also been published.<sup>3,4</sup> Recent research has shown that 2 genetically separate loci are responsible for the autosomal-dominant type of fibromatosis.<sup>5</sup> Females and males appear to be equally affected.

The gingival enlargement may occur alone or in conjunction with other abnormalities, as part of a syndrome, most commonly in association with hypertrichosis and epilepsy, with or without mental retardation. Other syndromes that

have occasionally been associated with hereditary gingival fibromatosis are Zimmerman–Laband syndrome (defects of bone, ear, nail and nose, accompanied by hepatosplenomegaly), Murray–Puretic–Drescher syndrome (multiple dental hyaline tumours), Rutherford syndrome (corneal dystrophy), Cowden syndrome (multiple hamartomas) and Cross syndrome (hypopigmentation with athetosis).<sup>6</sup>

More recently, hearing loss and supernumerary teeth have been associated with hereditary gingival fibromatosis.<sup>7</sup> The condition has also been reported in association with deficiency of growth hormone caused by lack of growth hormone release factor.<sup>8</sup>

On clinical examination, the enlarged gingivae appear normal in colour and feel firm and nodular on palpation. Exaggerated stippling may be present. Both the mandible and

the maxilla may be affected, and the enlargement may be localized or generalized. The maxillary tuberosities and the labial gingiva around the mandibular molars are usually involved in the localized form of gingival hyperplasia.

The typical histologic appearance of the affected tissue includes hyperplastic epithelium with elongated rete ridges extending deeply into the underlying connective tissue. Coarse and fine dense bundles of collagen, oriented in all directions, and a few “plump” fibroblasts have been described as making up the connective tissue layer. A more cellular specimen with large fibroblasts, small calcified particles and small foci of bone has also been described.<sup>9,10</sup> The histologic features are nonspecific, and a definitive diagnosis of hereditary gingival fibromatosis can be made only in the presence of an adequate history and clinical examination.

This report presents the clinical and histopathological features and the dental management, over a period of 4 years, of a young patient with hereditary gingival fibromatosis.

## Case Report

### *Clinical Presentation and Periodontal and Orthodontic Management*

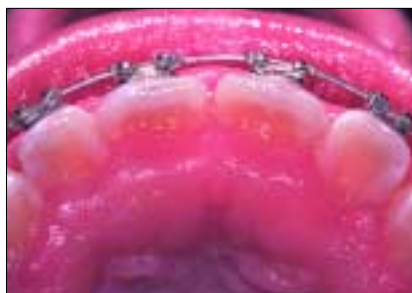A 13-year-old girl presented with a complaint of excessive “gum coverage” over her teeth. The patient and her parents were considering orthodontic treatment of her Class II, division 2 malocclusion, but after consultation their dentist advised that the amount of crown structure exposed on most

teeth was insufficient to allow accurate placement of the brackets.

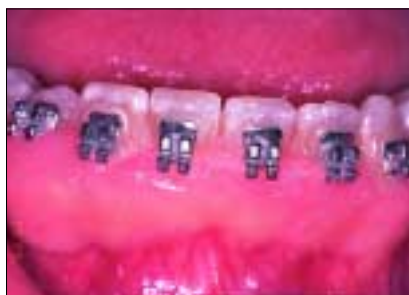The patient’s medical history appeared to be noncontributory, with the exception of occasional hypersensitivity reactions (rhinorrhea and lacrimation) to various household sources of antigens. Upon questioning, the patient’s mother disclosed that she, her brother and her father (the patient’s grandfather) had a history of gingival enlargement involving, to various extents, the maxilla as well as the mandible. The patient exhibited no signs of hypertrichosis or mental retardation and had no history of epilepsy or intake of medication known to cause gingival overgrowth. Although not aware of the age at onset of the original symptoms, the parents had noticed a delay in the eruption of certain permanent teeth such as the canines. The patient was especially concerned about the “gummy” appearance of her smile and the spacing between her maxillary anterior teeth.

Intraoral examination revealed that the patient was in the mixed dentition stage. The level of oral hygiene was fair, in spite of the reported difficulty of interproximal flossing, caused by the tissue overgrowth. The maxillary and mandibular dental arches showed generalized gingival fibromatosis affecting both the vestibular and lingual–palatal surfaces. The gingival enlargement was most evident in the maxillary and mandibular anterior regions.

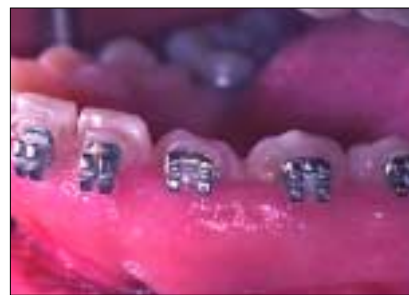Maxillary vestibular and palatal gingivectomy, with reverse bevel incisions, was performed from first molar to first molar (teeth 16 to 26), under local anesthesia, to obtain a smoother gingival contour. A biopsy sample of the gingival tissues was



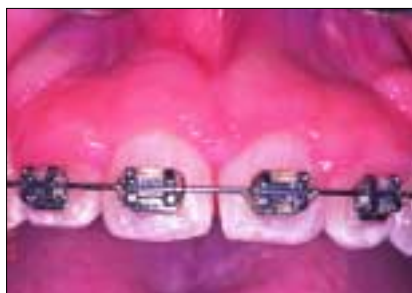**Figure 1a:** Representative photograph of relatively marked, recurrent gingival enlargement on the anterior palatal region.



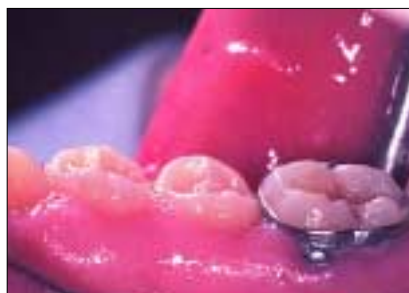**Figure 1b:** Mandibular anterior labial region showing recurrence of the gingival enlargement.



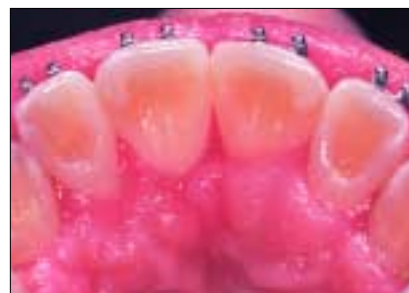**Figure 1c:** Recurrence of gingival enlargement in the mandibular cuspid–bicuspid area.



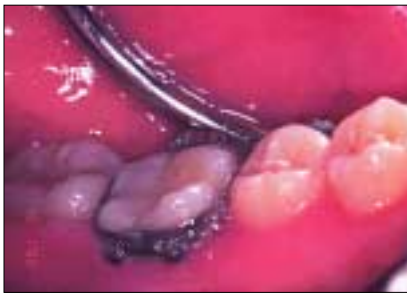**Figure 1d:** Recurrence of gingival enlargement in the maxillary anterior labial area.



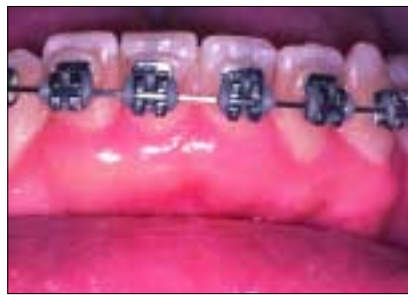**Figure 1e:** The mandibular bicuspid area exhibiting some recurrent gingival enlargement.



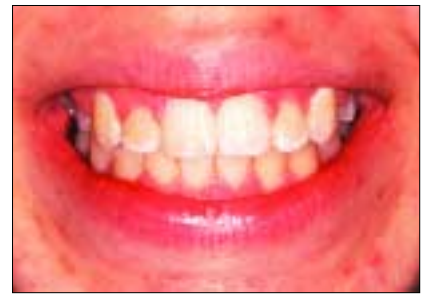**Figure 2a:** Representative photograph of the gingival tissue after gingivectomy in the palatal area where the tissue bulk has been reduced (compare with Fig. 1a).



**Figure 2b:** The mandibular posterior lingual tissue, effectively reduced.



**Figure 2c:** The orthodontic wires were replaced 3 weeks after the gingivectomy.



**Figure 3:** Photograph obtained during post-orthodontic follow-up one year after the gingivectomy procedure.

submitted for histologic evaluation. The deciduous maxillary left cuspid was removed at the same time as the gingival tissue was excised, because its root was totally resorbed and it was held in place only by the bulk of the gingiva. A similar situation was encountered for the deciduous mandibular right cuspid when the mandibular gingivectomy was performed. A postoperative dressing was applied. A month later, a similar procedure was performed for the mandible. During the second procedure cyanoacrylate was placed directly on the surgical site, before placement of the periodontal dressing. The rationale for doing so was to assist in the retention of the periodontal pack and to ensure hemostasis.

A 0.12% chlorhexidine gluconate rinse was prescribed for administration twice a day for 2 weeks. The patient was seen at 1, 3 and 5 weeks postoperatively. Postsurgical healing was uneventful, and, because the patient's oral hygiene was fair, orthodontic treatment and supportive periodontal therapy were initiated. Three years later, the patient exhibited full adult dentition and was receiving full fixed orthodontic treatment. At that time, recurrence of the fibromatosis was observed in all 4 quadrants. The condition was particularly prominent in the anterior palate, the maxillary and mandibular anterior labial regions, and the mandibular posterior buccal regions (Figs. 1a, 1b, 1c, 1d and 1e). The appearance of the tissues was very similar to that seen at the original presentation. It was apparent that the hyperplasia was not compatible with efficient orthodontic tooth movement. Accordingly, another gingivectomy procedure was undertaken so that the teeth could be orthodontically consolidated in their final positions and to achieve optimal esthetic appearance. Maxillary and mandibular gingivectomy was performed during 2 separate appointments, as described for the first procedures. There were no postoperative complications, and healing was again uneventful. The postoperative results are illustrated in Figs. 2a and 2b.

Three weeks after the periodontal surgery, orthodontic treatment was re-initiated with replacement of orthodontic wires (Fig. 2c). At the most recent follow-up, one year after the procedure, no recurrence of the hyperplasia was found. At that time the orthodontic treatment was considered to be successfully completed. A photograph obtained during the postorthodontic follow-up is shown in Fig. 3.

### **Histopathology**

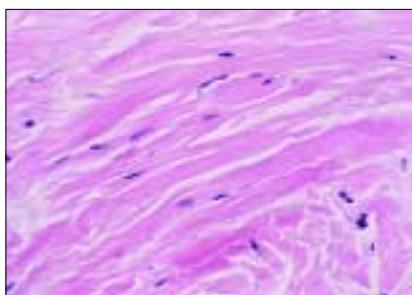
Microscopic examination of the specimens confirmed that the general appearance of the lesional tissue was consistent with that described previously for hereditary gingival hyperplasia: abundant, dense connective tissue in which markedly thickened fibre bundles alternated with relatively finer collagen fascicles, the fibre bundles being speckled with small, dark fusiform nuclei of fibroblastic cells with scanty cytoplasm (Fig. 4a); plump fibroblasts were seen only focally. Neurovascular bundles were well represented (Fig. 4b), but sparsely distributed neuronal axons (typical of neurofibroma) and palisading or streaming of cells (typical of neuromas or neurilemmomas) were not observed in the tissues. The surface epithelium was characteristically hyperplastic, exhibiting a pseudoepitheliomatous appearance (Figs. 4c and 4d).

### **Discussion**

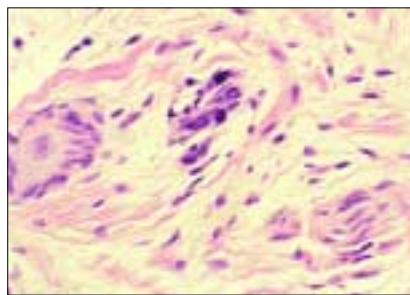
The mode of genetic transmission in this patient points to an autosomal dominant gene, because family members of both sexes were affected and the condition was present in successive generations (grandfather, mother and child). Hereditary gingival fibromatosis can occur as an isolated disorder or as part of a syndrome.<sup>1,7</sup> In this case, the patient did not exhibit any signs or symptoms suggesting that the condition was syndromic. The diagnosis was made on the basis of the clinical presentation, the family history, the pattern of recurrence and the characteristic microscopic features of the histology samples.

There is inconsistency in the literature as to the cellular and molecular mechanisms that lead to this condition. Some authors report an increase in the proliferation of gingival fibroblasts,<sup>11</sup> whereas others report slower-than-normal growth.<sup>12</sup> According to a recent report,<sup>11</sup> increased collagen synthesis rather than decreased levels of collagenase activity may be involved.

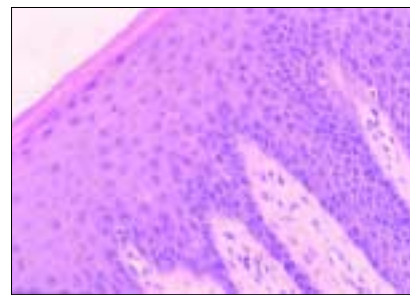
Hereditary gingival fibromatosis has been predominantly described as a benign condition. One case of focal epithelial dysplasia arising from the overgrown tissues has been reported, but the report did not make clear whether there was any causal relationship between the fibromatosis and the dysplasia.<sup>13</sup> Allowing the progressive eruption of the permanent dentition, improving cosmetics and restoring function are all considered valid reasons for reducing excessive tissue bulk. In this case a



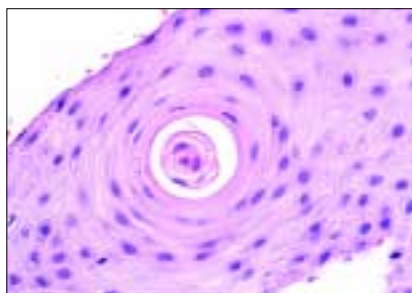
**Figure 4a:** Representative photomicrograph of a section from the gingivectomy specimen showing substantially thickened collagen fibre bundles.



**Figure 4b:** Neurovascular bundles are evident in the lesional tissue.



**Figure 4c:** Epithelial hyperplasia with pseudo-epitheliomatous rete ridges in a representative section.



**Figure 4d:** Pseudo-keratin pearl formation in the surface epithelium.

combination of delayed eruption, psychological and esthetic factors, and the need for efficient orthodontic tooth movement all dictated the course of treatment. Reports about recurrence rates are conflicting,<sup>14-16</sup> so the long-term benefit of periodontal reduction surgery cannot be predicted. In severe cases of hereditary gingival fibromatosis, full-mouth tooth clearance has been advocated, as some evidence<sup>15,16</sup> suggests that the condition does not recur if the teeth have been extracted. One report indicated that there is less chance of recurrence if the gingivectomy is delayed until the permanent dentition is in place.<sup>17</sup> However, in the case reported here, the deciduous teeth were retained and the permanent teeth were entrapped in the overgrown gingival tissue. Thus, delaying the gingivectomy with the goal of avoiding recurrence was contraindicated. We believe that as long as the patient is informed about the likelihood of recurrence, repeat gingivectomy is generally well accepted and well tolerated. With routine postoperative care and good oral hygiene, recovery is expected to be uneventful. In the case reported here, gingival enlargement did not recur to a significant degree sooner than 3 years after the original procedure, but in other cases more frequent follow-up might be required, with surgical correction of any specific sites as they present.

It is conceivable that orthodontic treatment might stimulate recurrence in some patients, especially if periodontal hygiene is impeded by the orthodontic appliance. In our case there has been no significant recurrence to date.

## Conclusions

This report outlines the diagnosis and treatment of a patient with hereditary gingival fibromatosis. Because this condition is rare, there are only a few case reports addressing its diagnosis, dental management and long-term treatment. This report underlines the role of orthodontics in positioning the teeth to allow optimal oral hygiene and adequate lip seal during swallowing. Proper tooth repositioning and lip seal prevent mouth-breathing, which might otherwise exacerbate the condition. Past research has focused mostly on the causes of drug-induced hyperplasias. A recent electron microscopic study of samples from patients with hereditary gingival fibromatosis suggests that the distribution of collagen fibres in this form of the condition is distinct from that seen in nonfamilial cases.<sup>18</sup> Recent investigations have yielded new invaluable information on the genetic and molecular mechanisms of gingival overgrowth,<sup>19-22</sup> but further research is needed to elucidate the etiology and complex pathogenesis of this condition. ♦

*La Dre Kelekis-Cholakis est une parodontiste en exercice privé et enseignante à temps partiel à la Division de parodontie, Faculté de médecine dentaire, Université du Manitoba, Winnipeg (Manitoba).*

*Le Dr Wiltshire est un orthodontiste en exercice privé et directeur du Département de dentisterie préventive, Faculté de médecine dentaire, Université du Manitoba.*

*La Dre Birek est professeure agrégée au Département de biologie buccale, Faculté de médecine dentaire, Université du Manitoba.*

*Écrire au : Dre Catalena Birek, Université du Manitoba, Faculté de médecine dentaire, 780, avenue Bannatyne, Winnipeg (Manitoba) R3E 0W2. Courriel : birek@ms.umanitoba.ca.*

*Les auteurs n'ont aucun intérêt financier déclaré.*

## Références

1. Fletcher JP. Gingival abnormalities of genetic origin: preliminary communication with special reference to hereditary gingival fibromatosis. *J Dent Res* 1966; 45(3):597-612.
2. Bozzo L, de Almedia OP, Scully C, Aldred MJ. Hereditary gingival fibromatosis. Report of an extensive four-generation pedigree. *Oral Surg Oral Med Oral Pathol* 1994; 78(4):452-4.
3. Jorgenson RJ, Cocker EM. Variation in the inheritance and expression of gingival fibromatosis. *J Periodontol* 1974; 45(7):472-7.
4. Singer SL, Goldblatt J, Hallam LA, Winters JC. Hereditary gingival fibromatosis with a recessive mode of inheritance. Case reports. *Aust Dent J* 1993; 38(6):427-32.

5. Hart IC, Pallos D, Bozzo L, Almeida OP, Marazita ML, O'Connell JR, and other. Evidence of genetic heterogeneity for hereditary gingival fibromatosis. *J Dent Res* 2000; 79(10):1758-64.
6. Gorlin RJ, Pinborg JJ, Cohen Jr MM. Syndromes of the head and neck. 2nd edition. New York: McGraw Hill; 1976. p. 329-36.
7. Wynne SE, Aldred MJ, Bartold MP. Hereditary gingival fibromatosis associated with hearing loss and supernumerary teeth — a new syndrome. *J Periodontol* 1995; 66(1):75-9.
8. Oikarinen K, Salo T, Kaar ML, Lahtela P, Altonen M. Hereditary gingival fibromatosis associated with growth hormone deficiency. *Br J Oral Maxillofac Surg* 1990; 28(5):335-9.
9. Raeste AM, Collan Y, Kilpinen E. Hereditary fibrous hyperplasia of the gingiva with varying penetrance and expressivity. *Scan J Dent Res* 1978; 86(5):357-65.
10. Zackin SJ, Weisberger D. Hereditary gingival fibromatosis. Report of a family. *Oral Surg Oral Med Oral Path* 1961; 14(7):828-36.
11. Tipton DA, Howell KJ, Dabbous MK. Increased proliferation, collagen and fibronectin production by hereditary gingival fibromatosis fibroblasts. *J Periodontol* 1997; 68(6):524-30.
12. Shirasuna K, Okura M, Watatani K, Hayashido Y, Saka M, Matsuya T. Abnormal cellular property of fibroblasts from congenital gingival fibromatosis. *J Oral Pathol* 1988; 17(8):381-5.
13. Redman RS, Ward CC, Patterson RH. Focus of epithelial dysplasia arising in hereditary gingival fibromatosis. *J Periodontol* 1985; 56(3):158-62.
14. Cuestas-Carnero R, Bornancini CA. Hereditary generalized gingival fibromatosis associated with hypetrichosis: report of five cases in one family. *J Oral Maxillofac Surg* 1988; 46(5):415-20.
15. Kharbanda OP, Sidhu SS, Panda SK, Deshmuck R. Gingival fibromatosis: study of three generations with consanguinity. *Quintessence Int* 1993; 24(3):161-4.
16. Danesh-Meyer MJ, Holbrow DW. Familial gingival fibromatosis: a report of two patients. *N Z Dent J* 1993; 89(398):119-22.
17. James PL, Prasad SV. Gingival fibromatosis: report of a case. *J Oral Surg* 1971; 29(1):55-9.
18. Barros SP, Marzel J, Cavalcanti de Araujo V, Paes de Almeida O, Bozzo L. Ultrastructural aspects of connective tissue hereditary gingival fibromatosis. *Oral Surg Oral Med Oral Pathol Oral Radiol Endod* 2002; 92(1):78-82.
19. Hart TC, Zhang Y, Gorry MC, Hart PS, Cooper M, Marazita ML, and others. A mutation in the SOS1 gene causes hereditary gingival fibromatosis type 1. *Am J Hum Genet* 2002; 70(4):943-54.
20. de Andrade CR, Cotrin P, Graner E, Almeida OP, Sauk JJ, Coletta RD. Transforming growth factor-beta1 autocrine stimulation regulates fibroblast proliferation in hereditary gingival fibromatosis. *J Periodontol* 2001; 72(12):1726-33.
21. Xiao S, Bu L, Zhu L, Zheng G, Yang M, Qian M, and others. A new locus for hereditary gingival fibromatosis (GINGF2) maps to 5q13-q22. *Genomics* 2001; 74(2):180-5.
22. Wright HJ, Chapple IL, Matthews JB. TGF-beta isoforms and TGF-beta receptors in drug-induced and hereditary gingival overgrowth. *J Oral Pathol Med* 2001; 30(5):281-9.