

# Autogenous Tooth Transplantation: An Alternative to Dental Implant Placement?

(Transplantation de dent autogène vs la pose d'un implant dentaire)

- Cameron M.L. Clokie, DDS, PhD, FRCD(C), Dip. ABOMS •
- Deirdre M. Yau, B.Sc., DDS •
- Laura Chano, DDS •

## S o m m a i r e

*La transplantation de dent autogène, ou autotransplantation, est le déplacement chirurgical d'une dent d'un endroit de la bouche à un autre chez un même individu. Jadis considérée comme étant expérimentale, l'autotransplantation a obtenu des taux élevés de réussite et est une excellente solution de rechange au remplacement de la dent. Bien que les indications pour l'autotransplantation soient limitées, une sélection judicieuse des patients couplée à une technique appropriée peut mener à des résultats esthétiques et fonctionnels exceptionnels. Un avantage de cette procédure est que la pose d'une prothèse fixée à un implant ou autre forme de remplacement de dent prothétique n'est pas nécessaire. Cet article souligne les indications pour la transplantation de dent autogène en se servant de 3 rapports de cas comme exemples. Enfin, les auteurs décrivent la technique chirurgicale recommandée et discutent des taux de réussite*

**Mots clés MeSH :** tooth/transplantation; tooth loss

© J Can Dent Assoc 2001; 67:92-6  
Cet article a fait l'objet d'une révision par des pairs.

The earliest reports of tooth transplantation involve slaves in ancient Egypt who were forced to give their teeth to their pharaohs.<sup>1</sup> However, allotransplantation — transplantation of a tooth from one individual to another — was eventually abandoned because of problems of histocompatibility and replaced with autotransplantation. Autogenous tooth transplantation, or autotransplantation, is the surgical movement in one individual of a vital or endodontically treated tooth from its original location in the mouth to another site.<sup>2</sup> Autogenous tooth transplantation was first well documented in 1954 by M.L. Hale. The major principles of his technique are still followed today.<sup>3</sup> The science of autotransplantation has progressed, as evidenced by the high success rates reported in studies over the past decade.<sup>1,4-8</sup> These studies demonstrate that autotransplantation is a viable option for tooth replacement for carefully selected patients.

### Indications

While there are many reasons for autotransplanting teeth, tooth loss as a result of dental caries is the most common indication, especially when mandibular first molars are involved. First molars erupt early and are often heavily restored. Autotransplantation in this situation involves the removal of a

third molar which may then be transferred to the site of an unrestorable first molar.<sup>2</sup> Other conditions in which transplantation can be considered include tooth agenesis (especially of premolars and lateral incisors), traumatic tooth loss, atopic eruption of canines, root resorption, large endodontic lesions, cervical root fractures, localized juvenile periodontitis as well as other pathologies.<sup>2,9-11</sup> Successful transplantation depends on specific requirements of the patient, the donor tooth, and the recipient site.

### Candidate Criteria

Patient selection is very important for the success of autotransplantation. Candidates must be in good health, able to follow post-operative instructions, and available for follow-up visits. They should also demonstrate an acceptable level of oral hygiene and be amenable to regular dental care. Most importantly, the patients must have a suitable recipient site and donor tooth. Patient cooperation and comprehension are extremely important to ensure predictable results.

### Recipient Site Criteria

The most important criteria for success involving the recipient site is adequacy of bone support. There must be sufficient

alveolar bone support in all dimensions with adequate attached keratinized tissue to allow for stabilization of the transplanted tooth. In addition, the recipient site should be free from acute infection and chronic inflammation.<sup>12</sup>

### **Donor Tooth Criteria**

The donor tooth should be positioned such that extraction will be as atraumatic as possible. Abnormal root morphology, which makes tooth removal exceedingly difficult and may involve tooth sectioning, is contraindicated for this surgery.<sup>1</sup> Teeth with either open or closed apices may be donors; however, the most predictable results are obtained with teeth having between one-half to two-thirds completed root development.<sup>1,6,7,9,12-16</sup> Surgical manipulation of teeth with less than one-half root formation may be too traumatic and could compromise further root development, stunting maturation or altering morphology. When root development is greater than two-thirds, the increased length may cause encroachment on vital structures such as the maxillary sinus or the inferior alveolar nerve.<sup>13</sup> Furthermore, a tooth with complete or near complete root formation will generally require root canal therapy, while a tooth with an open apex will remain vital and should continue root development after transplantation. In the latter case, successful transplantation without the need for further endodontic therapy is usually seen.

### **Case Reports**

Indications for tooth transplantation are discussed in the following 3 case reports. All 3 patients presented to the University of Toronto's dental faculty.

#### **Case 1**

A 17-year-old male orthodontic patient was referred to the oral and maxillofacial surgery department for the evaluation of an unerupted tooth 47. A panoramic radiograph revealed horizontally impacted teeth 47 and 48 (Fig. 1), complete root formation of tooth 47 and incomplete root formation of tooth 48. It was felt that orthodontic uprighting of tooth 47 was not possible and that it would be difficult to bring tooth 48 into an ideal position using an orthodontic approach. As tooth 48 demonstrated approximately two-thirds root formation, it was felt that transplantation of that tooth to position 47 could address this patient's problem, and the tooth was successfully transplanted.

#### **Case 2**

A 17-year-old female presented to the emergency clinic complaining of pain associated with tooth 37. A periapical radiograph showed extensive destruction of the crown of this tooth as a result of dental caries (Fig. 2). Examination led to a diagnosis of pulpal necrosis with periapical extension. Following consultation with the endodontic and prosthodontic departments, it was felt that the extent of the caries would make restoration of the tooth very difficult, if not impossible. Since the radiograph showed that tooth 38 had two-thirds root development, the decision was made to transplant tooth 38 to the space left following the extraction of tooth 37.

#### **Case 3**

In 1995, an 11-year-old female presented complaining of mobility associated with tooth 46. The patient was lost to follow-up until December 1998, at which time she was referred to the

graduate periodontal clinic for a complete examination. The patient was diagnosed with localized juvenile periodontitis, and removal of tooth 46 was advised due to a poor prognosis (Fig. 3). Otherwise, the overall prognosis was fair; all the other teeth could be retained and maintained for a prolonged period of time. Tooth transplantation was suggested to manage this patient's problem. Periapical radiographs of teeth 38 and 48 were taken. As the root development of tooth 48 appeared greater than two-thirds (Fig. 4a) and that of 38 was less (Fig. 4b), tooth 38 was chosen as the donor tooth.

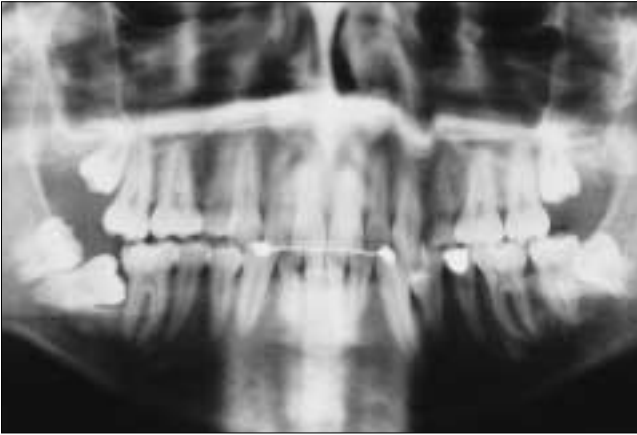
While no long-term follow-up is available for these cases, the six-month post-operative radiograph for case 3 (Fig. 5) shows good bone fill at the recipient site, continued development of the roots of the transplanted tooth, and development of the periodontal ligament space, which is characteristic of an appropriately healing autotransplant.

### **Surgical Technique**

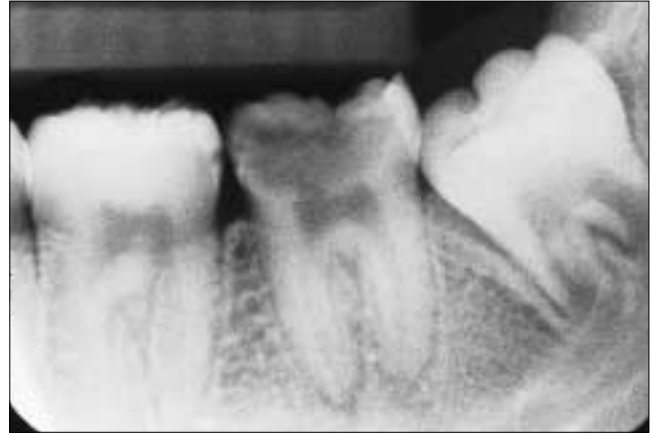The procedure for tooth transplantation is usually no more traumatic for the patient than the removal of impacted third molars. Depending on patient preference, local anesthesia alone or in conjunction with some form of sedation is sufficient for the surgical procedure. Once sufficient anesthesia is obtained, the tooth at the recipient site is extracted and the recipient socket prepared. Occlusal and periapical radiographs of the donor tooth should be used to determine its labiolingual and mesiodistal dimensions. Many practitioners use this information to fabricate an acrylic replica of the tooth to be transplanted. This replica allows them to prepare the recipient site using a guide with dimensions similar to those required for the donor tooth. Next, the donor tooth is carefully removed to ensure minimal trauma to the periodontal ligament. When the donor tooth is unerupted, extraction involves flap elevation, bone removal, and gentle removal of the follicle from around the crown. Traumatic injury to the root surface of the donor tooth will impair the success of the transplant due to inadequate periodontal ligament regeneration. This is important for integration at the recipient site.<sup>4</sup> Once removed, the donor tooth should be handled as little as possible and the practitioner should be careful to touch only the crown. The tooth is then placed in the recipient socket. Minimal delay between extraction and transplantation is important to ensure maintenance of periodontal membrane vitality. If further adjustment of the recipient socket is required, the donor tooth can be easily stored in its original socket.

Once the transplanted tooth is in its final position, occlusion is checked and, if needed, adjusted using a high-speed finishing bur. The tooth should be in slight infraocclusion to allow it to erupt into proper occlusion over the next few months. When proper positioning is obtained, the tooth can be stabilized with a suture splint for one to 2 weeks.<sup>17</sup> Alternatively, adhesive resin, light polymerizing resin, or a temporary bridge of autopolymerizing resin and wire splint can be used.<sup>14</sup>

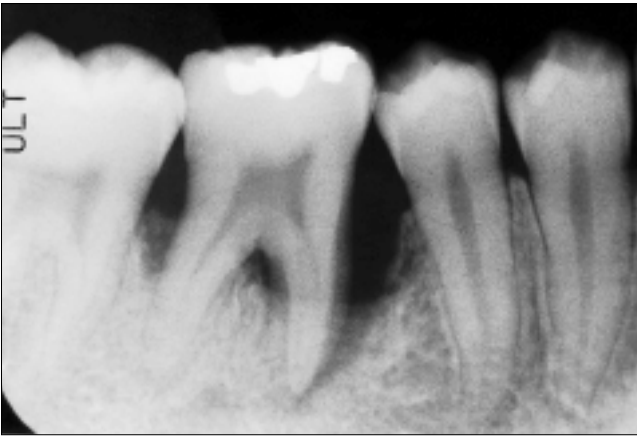
Post-operative instructions and sequelae are similar to those following the removal of an impacted tooth.<sup>2</sup> A soft diet should be followed for a couple of days after surgery and the patient should be instructed to avoid mastication on the transplant. Patients should be instructed to maintain optimal oral hygiene. Some investigators feel that the patient should rinse with chlorhexidine gluconate mouth rinse as an adjunct to oral



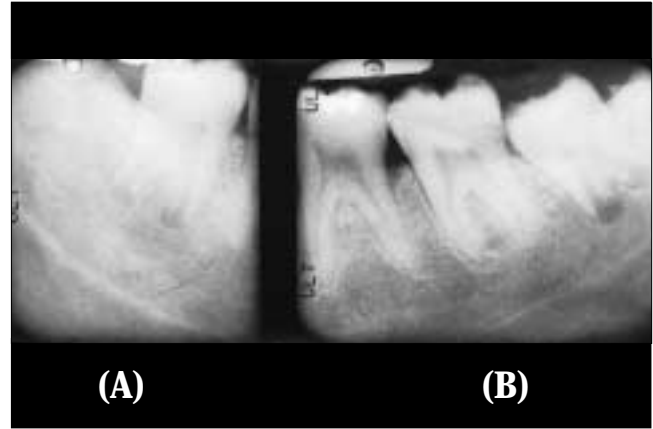
**Figure 1:** Panoramic radiograph revealing horizontally impacted teeth 47 and 48. Note the stage of root formation of tooth 48.



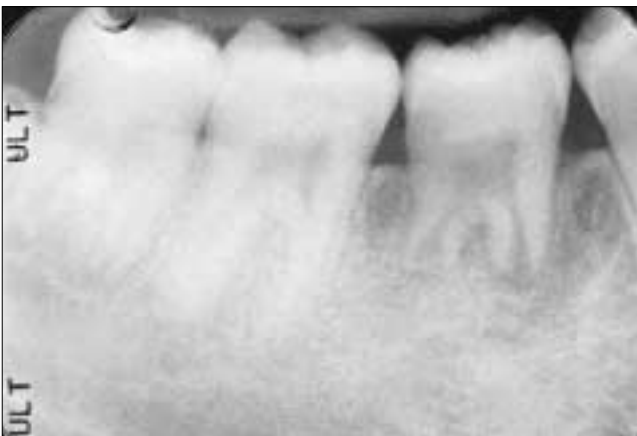**Figure 2:** Periapical radiograph of the left posterior mandible demonstrating extensive decay associated with tooth 37. Note the stage of root development of tooth 38.



**Figure 3:** Periapical radiograph showing localized juvenile periodontitis associated with tooth 46.



**Figure 4:** Periapical radiographs of the lower third molars show that root development of tooth 48 (a) appears greater than two-thirds; therefore, tooth 38 (b) was used as the donor tooth.



**Figure 5:** Six-month post-operative radiograph indicates patient has regained the supporting alveolar bone in the region of the tooth transplant and shows continued root development with the establishment of a periodontal ligament space.

hygiene.<sup>1</sup> Patients may also be given perioperative and post-operative antibiotics.<sup>1,4,6,14,17</sup>

Many clinicians recommend that patients be seen the day after surgery to ensure the transplant has retained its new position, the splint is stable, and that swelling, edema, and hematoma formation are within normal limits.<sup>15</sup> The patient should then be seen at weekly intervals for one month if there are no complications. After one month, the patient should be seen every 6 months for 2 years.<sup>18</sup> During this period the tooth should be evaluated for the onset of pulpal breakdown seen as intrapulpal calcification, periapical radiolucency, or root resorption. For vital transplants of developing teeth with open apices, endodontic treatment of the transplant is not required as these teeth can be revascularized and reinnervated.<sup>2</sup> However, endodontic treatment is always required for transplants of mature teeth with complete root formation. Endodontic therapy begins approximately one month post-operatively with instrumenting of the canals and filling with calcium hydroxide. Gutta percha filling is completed 3 to 6 months post-transplantation.<sup>4</sup>

## Success

The literature reports excellent success rates following tooth transplantation when the appropriate protocol is followed. Andreasen<sup>5</sup> found 95% and 98% long-term survival rates for incomplete and complete root formation of 370 transplanted premolars observed over 13 years. Lundberg and Isaksson<sup>6</sup> had success in 94% and 84% of cases for open and closed apices respectively in 278 autotransplanted teeth over 5 years. Kugelberg<sup>7</sup> achieved success rates of 96% and 82% for 45 immature and mature teeth transplanted into the upper incisor region over 4 years. Cohen<sup>1</sup> showed success in the ranges of 98-99% over 5 years and 80-87% over 10 years with transplanted anterior teeth with closed apices. Nethander<sup>4</sup> found 5-year success rates of over 90% for 68 mature teeth transplanted with a 2-stage technique. Josefsson<sup>8</sup> found 4-year success rates of 92% and 82% respectively for premolars with incomplete and complete root formation.

These consistently high success rates are a contrast to the variable results reported in many older studies. Schwartz and others<sup>16</sup> yielded success rates of only 76.2% at 5 years and 59.6% at 10 years. Similarly, Pogrel<sup>13</sup> found that his success rate for 416 autotransplanted teeth was 72%. However, other investigators of that era had more positive results. Kristerson,<sup>11</sup> for example, obtained a success rate of 93% when 100 autotransplanted premolars were observed for a mean of 6.3 years.

The factors that lead to success have been extensively investigated. The most significant determinant for survival of the transplant is the continued vitality of the periodontal membrane. In cases where the periodontal ligament is traumatized during transplantation, external root resorption and ankylosis is often noted.<sup>1,13</sup> Schwartz<sup>16</sup> tried to link the loss of the graft to specific prognostic factors and found that success rates are highest when donor teeth are premolars, have one-half to two-thirds root development, and experience minimal trauma and limited extraoral time during surgery. The experience of the surgeon also affects the success because this procedure is technique-sensitive.

Although retention of the tooth and restoration of the edentulous space is the desired outcome for patients, more specific parameters have been used to measure the health of the surviving transplant. These parameters include marginal periodontal attachment, mobility, pain, root resorption, root development, sensitivity to percussion, gingival pocket depth, presence of gingivitis, and presence of fistulae.<sup>4,19,20</sup> However, these studies are difficult to compare because each used different measures to determine success.

The most common cause of failure of the autotransplant is chronic root resorption.<sup>15</sup> More specifically, the causes of tooth loss following transplantation from most common to least common are inflammatory resorption, replacement resorption (ankylosis), marginal periodontitis, apical periodontitis, caries, and trauma.<sup>16</sup> Inflammatory resorption may become evident after 3 or 4 weeks, while replacement resorption may not become evident until 3 or 4 months after transplantation. The incidence of both types of resorption can be decreased with atraumatic extraction of the donor tooth and immediate transfer to the recipient site to minimize the risk of injury to the periodontal ligament.<sup>1</sup>

## Conclusion

Although autotransplantation has not been established as a traditional means of replacing a missing tooth, the procedure warrants more consideration. Recent studies clearly demonstrate that autotransplantation of teeth is as successful as endosseous dental implant placement. Minimum acceptable success rates for endosseous titanium dental implants are 85% after 5 years and 80% after 10 years.<sup>21</sup> For younger patients, autotransplantation may also be considered as a temporary measure. The transplant can replace missing teeth to ensure preservation of bone until growth has ceased and then, if necessary, the patient can become a candidate for implants.<sup>22</sup> With appropriate patient selection, and presence of a suitable donor tooth and recipient site, autogenous transplantation should be considered as a viable option for treatment of an edentulous space. ♦

*Le Dr Clokie est directeur du Département de chirurgie buccale et maxillo-faciale à l'Université de Toronto.*

*Le Dr Yau est une interne en médecine dentaire à l'Hôpital Mount Sinai, Toronto (Ontario).*

*Le Dr Chano est résidente en parodontie, Université de Toronto.*

*Écrire au : Dr Cameron M. L. Clokie, Département de chirurgie buccale et maxillo-faciale, Université de Toronto, 124, rue Edward, Toronto, ON M5G 1G6. Courriel : cameron.clokie@utoronto.ca*

*Les auteurs n'ont aucun intérêt financier déclaré.*

## Références

1. Cohen AS, Shen TC, Pogrel MA. Transplanting teeth successfully: autografts and allografts that work. *JADA* 1995; 126(4):481-5.
2. Leffingwell CM. Autogenous tooth transplantation: a therapeutic alternative. *Dent Surv* 1980; 56(2):22-3, 26.
3. Hale ML. Autogenous transplants. *Oral Surg Oral Med Oral Pathol* 1956; 9:76-83.
4. Nethander G. Periodontal conditions of teeth autogenously transplanted by a two-stage technique. *J Periodontol Res* 1994; 29(4):250-8.
5. Andreasen JO, Paulsen HU, Yu Z, Bayer T, Schwartz O. A long-term study of 370 autotransplanted premolars. Part II. Tooth survival and pulp healing subsequent to transplantation. *Eur J Orthod* 1990; 12(1):14-24.
6. Lundberg T, Isaksson S. A clinical follow-up study of 278 autotransplanted teeth. *Br J Oral Maxillofac Surg* 1996; 34(2):181-5.
7. Kugelberg R, Tegsjö U, Malmgren O. Autotransplantation of 45 teeth to the upper incisor region in adolescents. *Swed Dent J* 1994; 18(5):165-72.
8. Josefsson E, Brattstrom V, Tegsjö U, Valerius-Olsson H. Treatment of lower second premolar agenesis by autotransplantation: four-year evaluation of eighty patients. *Acta Odontol Scand* 1999; 57(2):111-5.
9. Kahnberg KE. Autotransplantation of teeth: indications for transplantation with a follow-up of 51 cases. *Int J Oral Maxillofac Surg* 1987; 16(5):577-85.
10. Tegsjö U, Valerius-Olsson H, Frykholm A, Olgart K. Clinical evaluation of intra-alveolar transplantation of teeth with cervical root fractures. *Swed Dent J* 1987; 11(6):235-50.
11. Kristerson L, Lagerstrom L. Autotransplantation of teeth in cases with agenesis or traumatic loss of maxillary incisors. *Eur J Orthod* 1991; 13(6):486-92.
12. Northway WM, Konigsberg S. Autogenic tooth transplantation: the "state of the art". *Am J Orthod* 1980; 77(2):146-62.
13. Pogrel MA. Evaluation of over 400 autogenous tooth transplants. *J Oral Maxillofac Surg* 1987; 45(3):205-11.
14. Akiyama Y, Fukuda H, Hashimoto K. A clinical and radiographic study of 25 autotransplanted third molars. *J Oral Rehabil* 1988; 25(8):640-4.

15. Robinson PJ, Grossman LI. Tooth Transplantation. In: Robinson PJ, Guernsey LJ, eds. Clinical transplantation in dental specialties. St. Louis: C.V. Mosby Co.; 1980. p. 77-88.
16. Schwartz O, Bergmann P, Klausen B. Autotransplantation of human teeth: a life-table analysis of prognostic factors. *Int J Oral Surg* 1985; 14(3):245-58.
17. Andreasen JO, Paulsen HU, Yu Z, Ahlquist R, Bayer T, Schwartz O. A long-term study of 370 autotransplanted premolars. Part I. Surgical procedures and standardized techniques for monitoring healing. *Eur J Orthod* 1990; 12(1):3-13.
18. Tsukiboshi M. Autogenous tooth transplantation: a reevaluation. *Int J Periodontics Restorative Dent* 1993; 13(2):120-49.
19. Andreasen JO, Paulsen HU, Yu Z, Schwartz O. A long-term study of 370 autotransplanted premolars. Part III. Periodontal healing subsequent to transplantation. *Eur J Orthod* 1990; 12(1):25-37.
20. Andreasen JO, Paulsen HU, Yu Z, Bayer T. A long-term study of 370 autotransplanted premolars. Part IV. Root development subsequent to transplantation. *Eur J Orthod* 1990; 12(1):38-50.
21. Smith DE, Zarb GA. Criteria for success of osseointegrated endosseous implants. *J Prosthet Dent* 1989; 62(5):567-72.
22. Thomas S, Turner SR, Sandy R. Autotransplantation of teeth: is there a role? *Br J Orthod* 1998; 25(4):275-82.

LE CENTRE DE  
DOCUMENTATION  
DE L'ADC

Le Centre de documentation peut offrir aux membres toute référence citée dans cet article. Tél. : 1-800-267-6354 ou (613) 523-1770, poste 2223; téléc. : (613) 523-6574; courriel : [info@cda-adc.ca](mailto:info@cda-adc.ca).

CENTRE DE  
DOCUMENTATION  
DE L'ADC

Les services suivants sont offerts aux membres de l'ADC :

**recherches documentaires  
livres et vidéos (prêts)  
tables des matières  
dossiers de documentation  
services de référence  
articles de périodiques dentaires  
accès à un réseau d'information**

**Dossiers à moitié prix**

Les membres peuvent commander les dossiers suivants du Centre de documentation de l'ADC (version anglaise seulement) pour la somme de 5 \$ chacun (taxes applicables en sus), au lieu du prix régulier de 10 \$. Cette offre est valable jusqu'au 28 février 2001.

La détection des caries

Les soins dentaires aux immunodéprimés

L'échec de l'implant dentaire

La santé dentaire et la nutrition

Les inlays et les onlays

Les blessures d'aiguilles

L'évaluation du cabinet

La désaccoutumance au tabac

Le stress et l'épuisement professionnel au cabinet dentaire

Les troubles de l'ATM - diagnostic et traitement

La gestion des déchets et l'amalgame dentaire

**Pour commander un ou plusieurs de ces dossiers de documentation, ou en savoir plus sur nos services et frais, communiquez avec le Centre de documentation de l'ADC, tél. : 1-800-267-6354 ou (613) 523-1770, poste 2223; téléc. : (613) 523-6574; courriel : [info@cda-adc.ca](mailto:info@cda-adc.ca).**