

PRATIQUE
CLINIQUE



Midfacial Complications of Prolonged Cocaine Snorting

(Complications mi-faciales des renifleurs de cocaïne chroniques)

Peter D. Villa, DDS, FRCD(C)

SOMMAIRE

L'ingestion chronique aiguë de cocaïne prédispose les toxicomanes à une grande variété de complications locales et systémiques. Le présent article décrit le cas d'un renifleur de cocaïne de 38 ans qui, après des années d'abus de cette substance, a développé une érosion de son anatomie mi-faciale et des sinusites récurrentes. Ce dernier fait également rapport d'études de cas récemment publiées à cet égard et des effets bucco-dentaires systémiques et du comportement de l'abus de cocaïne.

Mots clés MeSH : case report; cocaine; substance-related disorders.

© J Can Dent Assoc 1999; 65:218-23

Cet article a fait l'objet d'une révision des pairs.

It is estimated that two million Americans are addicted to cocaine.¹ In Ontario, a survey by the Addiction Research Foundation found that almost 5% of the adult population had used cocaine at least once in their lifetime.² Much of the recent literature on this subject has focused on the behavioural and systemic effects of cocaine abuse as well as on drug interaction considerations for the management of dental patients who are addicts.³⁻⁹ This article describes the devastating midfacial deterioration suffered by a cocaine snorter. A brief overview of the clinical dental findings is provided and considerations for the management of patients with cocaine abuse problems are discussed.

Case Report

On February 3, 1998, a 38-year-old man was seen for evaluation of an oral-nasal communication after having been referred by his family dentist. The patient described how

problems began to manifest themselves as nosebleeds in July 1997 and how, during the following months, those symptoms progressed to recurrent sinus infections. He first noticed a "pinhole" in his palate in late November 1997, after a soft drink he consumed ran out his nose. The opening became larger over the next two months, stabilizing in size to the diameter of his little finger. The patient discovered that a thick layer of bubble gum could be used to cover the defect, normalize his speech, and prevent food stuffs from being displaced into his nose.

The patient's medical history indicated years of repeated cocaine snorting and a smoking habit of one-half pack of cigarettes per day. He was employed as a labourer, renovating the interior of commercial buildings.

The patient displayed a saddle-nose deformity, characterized by a broad, flat nose (Fig. 1). There was

no facial swelling, cervical lymphadenopathy, intraoral swelling, or trismus. Primary tooth 53 was deeply decayed and permanent cuspid tooth 13 was erupting palatally. A 10 x 12 mm oval fistula was apparent through the roof of his palate, just left of the midline, in the first molar area. No drainage or exophytic lesions were apparent.

Midline Lethal Granuloma, Wegener's Granulomatosis, nasal lymphoma, and tertiary syphilis can all present with these clinical findings.¹⁰⁻¹² The patient's workup therefore included a biopsy of the palatal mucosa, computed tomography (CT) scans, ear, nose and throat (ENT) evaluation, complete blood count (CBC), sedimentation rate, antinuclear antibody test (ANA), venereal disease test (VDRL), chest x-ray, and urinalysis. After consultation with specialists in other disciplines, results of these tests increased our confidence that we were dealing only

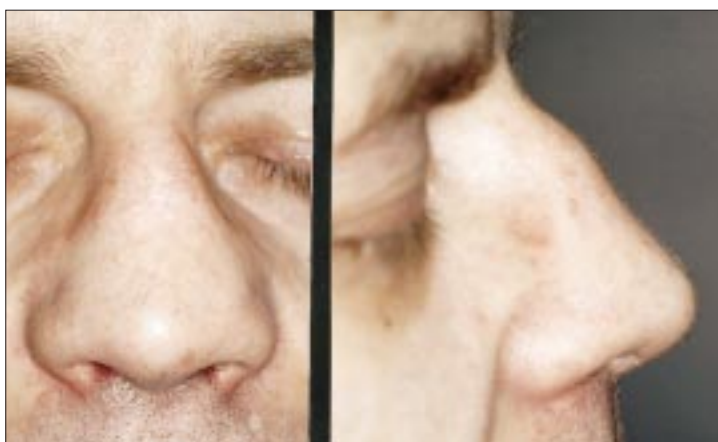


Fig. 1: Saddlenose deformity, front and side views.

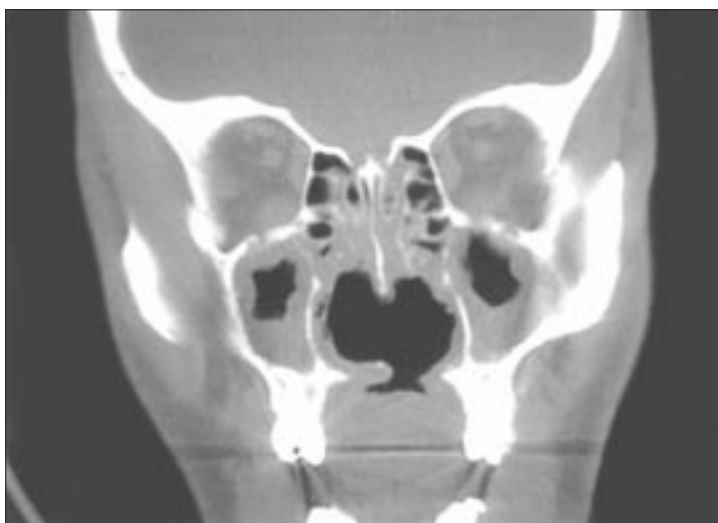


Fig. 2a: CT scan showing palatal perforation, loss of nasal septum and turbinates, and thickening of the maxillary sinus membranes.

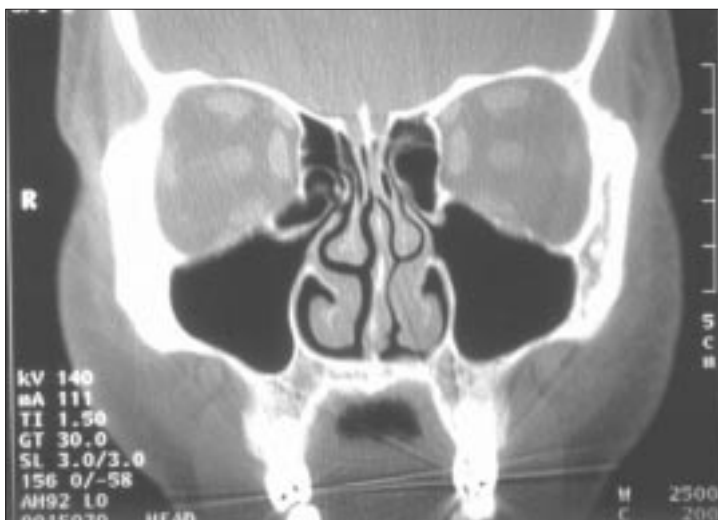

Fig. 2b: CT scan of normal midfacial anatomy.

with the local effects of cocaine abuse. **Figure 2a** is a CT scan of the patient's nasopalatal defect, while **Fig. 2b** shows a CT scan of a normal midfacial anatomy.

The biopsy of soft tissue, taken from the palatal margin of the oral-nasal opening, revealed a non-specific ulcer and chronic inflammation with some eosinophils. The presence of eosinophils has been noted in pathologists' findings, as reported in Armstrong and Shikani¹⁰ and Schweitzer.¹³

Management was predicated on complete cessation of the drug. The patient was informed of the consequences of continued cocaine use, and how to get help in quitting. He was also advised to smoke less, and to use a proper filtration mask while at work. Appropriate management of recurrent sinus infections was coordinated with his family physician. After basic oral hygiene and restorative procedures were provided, a removable obturator was constructed (**Fig. 3a, 3b** and **3c**). The patient will be re-evaluated for possible surgical closure of the oral-nasal fistula at a later date.

Pharmacology

Cocaine is a naturally occurring alkaloid. It is extracted from the leaves of the *Erythroxylon coca* plant, which is indigenous to three countries in northern South America.⁴ Cocaine is a psychologically disruptive and dependence-inducing drug; classified as a psychostimulant, it exhibits both local anesthetic and neurotransmitter effects.^{5,11,13} Like lidocaine, it functions as a local anesthetic by blocking the sodium channels of neural tissues, and like lidocaine, can trigger seizures at higher doses.¹⁴ Its neurotransmitter effects are attributed to a blocking action on the reuptake of specific transmitter agents by the presynaptic nerve endings. The resultant excess of neurotransmitter causes increased stimulation of the postsynaptic nerves. Dopamine activity is enhanced in the brain, causing a feeling of euphoria.¹⁵ Peripherally, norepinephrine is the transmitter whose activity is increased.¹¹ This profound enhancement of sympa-

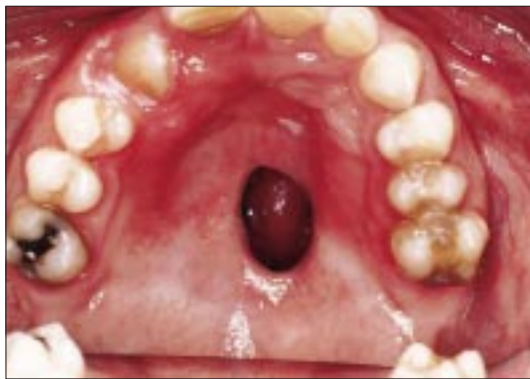

Fig. 3a: Nasopalatal defect.

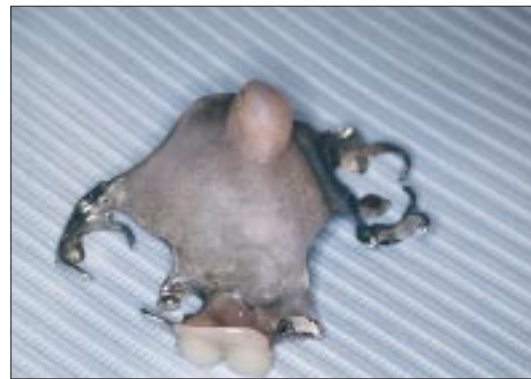

Fig. 3b: Obturator removed.

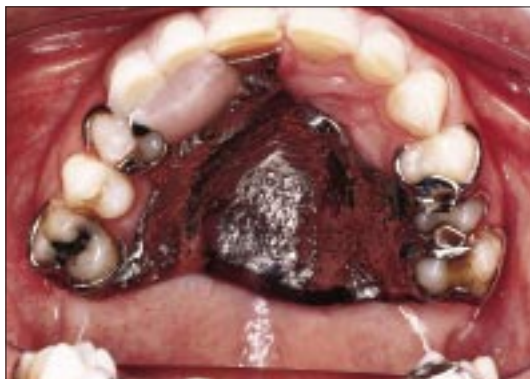

Fig. 3c: Obturator inserted.

thetic tone is responsible for the vasoconstrictive, tachycardiac, and dysrhythmic actions of the drug.^{6,8,14,16,17}

Cocaine also affects pulmonary physiology. By acting at the level of the medulla, an increase of the respiratory rate is produced.⁴ It has been postulated that vasoconstriction of the pulmonary circulation reduces blood flow sufficient to induce hypoxia.⁴ This is significant when one considers that the cardiovascular effects of cocaine profoundly increase myocardial oxygen demand while simultaneously vasoconstricting the coronary arteries.⁵ The potential then exists for myocardial infarction, pulmonary edema, circulatory collapse, and death.^{6,16}

Cocaine is well absorbed from mucous membranes and the gastrointestinal mucosa. It is rapidly degraded by hepatic and plasma esterases to water soluble metabolites that are excreted in the urine.^{5,16} Peak blood levels occur within 30 minutes, with most of the drug gone within two hours.¹⁸

While trace amounts of cocaine may be found in the bloodstream for eight to 12 hours after drug use, metabolites may be present for ten days.⁵

Cocaine is commonly taken intravenously, by smoking or inhalation of the "crack" or "free-base" form, or by snorting.^{5,8,13} Although less common, cocaine can also be topically applied to gingival tissues, or ingested orally (mixed with cocktails).^{13,19,20} Cocaine has an acidic pH of 4.0; its purity and sterility, and the type of adulterants it is mixed with, all directly affect its potential for local and systemic complications.^{17,21,22} HIV, hepatitis, and endocarditis are more prevalent in the population of intravenous drug abusers.^{3,5,7,13,16}

Clinical Findings of Cocaine Abuse

The street form of cocaine is both vasoconstricting and locally irritating to the thin respiratory epithelium of the nasal airway. Repeated snorting sets up a cascade of ischemia, inflammation,

micronecrosis, infection, and then macronecrosis leading to perforation.^{11,23} Nasal septum perforations of both the cartilaginous and bony tissues have been well documented.^{3,24} With larger defects, support of the nose is compromised, resulting in the typical saddle-nose deformity.^{3,24} Some patients have been known to use various narrow instruments to debride intranasal crusting, increasing the potential for perforations.¹¹ In extreme cases, adjacent bony structures may become eroded and vital tissues damaged.^{6,12,13,22,23}

Similarly, topically applied cocaine can be locally destructive to the oral mucosa and dentition. Acute ulceration, necrosis, and rapid recession of gingival tissues, as well as erosion of both dentin and enamel, have been reported.^{19,20} Inhalation of "crack" cocaine has been implicated in the corrosion of gold dental restorations.²⁵ Moreover, cocaine consumption immediately before or after tooth extraction can result in excessive hemorrhage.²⁶

Several publications list other oral findings that are indirectly associated with cocaine abuse.^{4,7,20,25} Patients with a substance abuse problem will frequently display higher rates of decay and periodontal disease as a result of general neglect.^{4,7,25} Chronic cocaine users often develop bruxing habits and demonstrate patterns of severe occlusal wear.^{4,7,20} Aggressive tooth brushing while on a "cocaine high" has been implicated as the cause of both cervical

Table I
Orofacial Signs and Symptoms of Chronic Cocaine Abuse

| Snorting | Gingival application |
|--|--|
| <ul style="list-style-type: none"> • loss of nasal hairs • nasal crusting • sinusitis/halitosis • epistaxis • nasal septal defect • saddlenose deformity • palatal perforation • erosion of turbinates, ethmoids, medial sinus walls, cribriform plate, and orbital walls • loss of smell • loss of visual acuity/diplopia • CSF leak | <ul style="list-style-type: none"> • mucosal ulceration • necrotizing ulcerative gingivitis • rapid gingival recession • dental erosion • possible corrosion of gold restorations |

Table II
Effects of Cocaine Abuse

| Cardiovascular effects | Central and behavioural effects |
|---|--|
| <ul style="list-style-type: none"> • hypertension • tachycardia • dysrhythmia • hypoxia • myocardial infarction • hemorrhagic stroke • pulmonary edema • dissection or rupture of aortic aneurysm • cardiac arrest | <ul style="list-style-type: none"> • sense of well-being, grandiosity • elation • anorexia • restlessness, agitation • nausea • headache • psychotic states/paranoia • pupillary dilation • tachypnea • hyperpyrexia • seizures |

tooth abrasion and gingival lacerations.^{4,7} Xerostomia and oral candida infections are also more common in this patient population.^{4,7,25}

Literature Review

The case of a 37-year-old woman who developed a palatal defect several years after a nasal septal perforation is described by Sastry and others.¹¹ Her long history of cocaine abuse continued despite initial violation of the septal structure. The authors postulate that vigorous self-debridement of intranasal crusts with cotton swabs, pens, and pencils contributed to the perforation process. Unfortunately, such debridement is well tolerated because of the profound local anesthetic effects of cocaine.

In another case, Sawicka and Trosser detail the findings of a 34-

year-old man who presented himself at the hospital with a six-day history of clear nasal discharge and malaise.²³ The patient, who had lost his sense of smell, admitted to a 19-year habit of cocaine snorting. A CT scan showed bone loss of the cribriform plate, and suggested a cerebrospinal fluid (CSF) leak through the right ethmoid sinus. A bifrontal craniotomy and fascia lata graft were performed to correct the persistent leak. The cribriform plate was noted to be paper thin and mobile. Histology of the olfactory bulb showed chronic inflammation change and gliosis.²³

Cocaine abuse can cause other complications. Newman and others report the case of a 43-year-old man with bilateral optic neuropathy and osteolytic sinusitis, secondary to cocaine abuse.²² The patient had initially described "holes" in his vision that pro-

gressed over a six-month period. He admitted to a 15-year history of daily intranasal cocaine use. MRI studies revealed extensive bony destruction of the nasal cavity, paranasal sinuses, the floor of the anterior cranial fossa, and the anterior surface of the clivus. After a four-month cessation of cocaine use, his visual acuity stabilized and his visual field deficits had not progressed.²²

Schweitzer describes two patients with severe and different complications as a result of cocaine abuse.¹³ The first patient developed total nasal septal necrosis, saddlenose deformity, and osteolytic sinusitis from chronic snorting. Her presenting symptoms included a five-year history of postnasal drainage, halitosis, intermittent epistaxis, and rhinitis. After a proper workup and detoxification, the patient underwent bilateral anrostomies and nasal reconstruction with auricular cartilage. With daily saline lavages of the nose and sinuses, her perinasal symptoms subsided. The second patient experienced tracheobronchial rupture with subcutaneous emphysema and pneumomediastinum after smoking "freebase" cocaine.

One of the most destructive cases of intranasal cocaine abuse to have been documented appears in the journal *Revista Medica de Panama*, where Sousa and Rowley detail the presenting complications, progression, and eventual death of a 22-year-old woman.¹² In this case, the patient described a two-year history of nasal obstruction, halitosis, progressive destruction of the septum and hard palate, purulent rhinorrhea, intense facial pain, strabismus, blindness in her left eye, and a recent reduction in the visual acuity in her right eye. Her diagnostic workup included physical, ophthalmoscopic, and rhinoscopic examinations, multiple biopsies, bacterial and fungal cultures, and CT scans. These studies confirmed the absence of the nasal septum, turbinates, and medial walls of the maxillary sinuses. They also revealed sclerosis at the base of the skull and a midline lesion

extending from the ethmoid sinuses to the orbital apexes. Initial treatment with prednisone and antibiotics resulted in improvement of the visual acuity in her right eye and resolution of the retro-ocular pain. Several months later, suspected of having renewed her drug habit, the patient was readmitted to hospital with meningitis. Her level of consciousness began to deteriorate on the twelfth day. A brain scan revealed an abscess within her frontal lobe. An emergency craniotomy was performed. The patient remained comatose and on a ventilator for 15 days. Death occurred as a result of *Pseudomonas pneumonia*.

Other cases of brain abscesses resulting from habitual cocaine snorting have been reported.^{21,27} Possible routes of bacterial inoculation include direct spread through the areas of osteitis (i.e. cribriform plate, frontal sinus) or as a septic thrombophlebitis spread along the associated valveless venous vasculature.²¹ These expanding cerebral abscesses are usually fatal.^{12,21}

Summary

Recreational drug use is reaching epidemic levels in North America. There are numerous considerations in the provision of dental care for patients with a cocaine abuse problem. Given the fundamental importance of identifying whether cocaine is a factor in the patient's management, the dentist should look for signs and symptoms indicating an abuse problem (Tables I and II). An appropriate medical history, a detailed examination of the orofacial anatomy, routine vital signs, and an understanding of the behavioural characteristics of an addict will help the practitioner recognize patients suspected of cocaine abuse. A patient with a substance abuse problem will frequently exhibit "drug-seeking" behaviour.

The family dentist should know that the injection of local anesthetic with epinephrine must be avoided for at least six hours after cocaine consumption.¹⁸ Some sources suggest the use of epinephrine in either local anesthetic or

retraction cord is contraindicated for at least 24 hours after cocaine use to prevent "sympathetic overload" resulting in a hypertensive crisis, cerebrovascular bleed, myocardial infarction, tachydysrhythmias, and/or cardiac arrest.^{21,28} Lidocaine without vasoconstrictors will have an additive effect with existing cocaine in reducing the patient's threshold for seizure activity.^{4,5} As well, general anesthesia poses significant cardiovascular risk and should be avoided with the chronic cocaine user.⁴

Ingesting powdered cocaine orally or nasally can be extremely destructive to the periodontal and midfacial anatomy. Once alerted to an abuse problem, the informed dentist can educate his or her patient about the progressive consequences of continued usage and provide a referral for professional counselling. Dental treatment should be deferred to an appropriate time when life-threatening complications can be avoided. Then, successful restorative, periodontal, and even obturator therapy can be provided.

An understanding of and vigilance for cocaine abuse in the dental patient can reduce, but will not eliminate, the potential for a related crisis in the dental office. Dental practitioners and their staff should remain capable of recognizing and managing a cocaine-related medical emergency. Dentists and dental societies must continue to educate the general public about the local and systemic hazards of this drug. ■

Dr. Villa is an oral and maxillofacial surgeon and head of dentistry at The Sudbury Regional Hospital in Ontario. He also maintains a private practice in Sudbury.

Acknowledgments: A special thanks to Olivia Simonetti for her translation services in the preparation of this article and to Dr. Michael Hamilton for his services in the care of the patient described in this case report.

Reprint requests to: Dr. Peter D. Villa, 306-2009 Long Lake Rd., Sudbury, ON P3E 6C1

References

- Gawin FH. Cocaine abuse and addiction. *J Fam Pract* 1989; 29:193-7.
- Adlaf EM, Ivis F, Walsh G, and Bondy S. Alcohol, tobacco, and illicit drug use amongst Ontario adults. 1977-1996. Survey by the Addiction Research Foundation.
- Laskin DM. Looking out for the cocaine abuser. *J Oral Maxillofac Surg* 1993; 51:111.
- Lee CY, Mohammadi H, and Dixon RA. Medical and dental implications of cocaine abuse. *J Oral Maxillofac Surg* 1991; 49:290-3.
- Goldstein FJ. Toxicity of cocaine. *Compendium* 1990; 11:710, 712, 714-6.
- Pallasch TJ, McCarthy FM, and Jastak JT. Cocaine and sudden cardiac death. *J Oral Maxillofac Surg* 1989; 47:1188-91.
- Friedlander AH, Gorelick DA. Dental management of the cocaine addict. *Oral Surg Oral Med Oral Pathol* 1988; 65:45-8.
- Isaacs SO, Martin P, and Willoughby JH. "Crack" (an extra potent form of cocaine) abuse: a problem of the eighties. *Oral Surg Oral Med Oral Pathol* 1987; 63:12-6.
- Ravi VS, Zmyslowski WP, and Marino J. Probable cocaine-induced hyperthermia in an anesthetized patient: a case report. *J Oral Maxillofac Surg* 1993; 51:204-5.
- Armstrong M Jr, Shikani AH. Nasal septal necrosis mimicking Wegener's granulomatosis in a cocaine abuser. *Ear Nose Throat J* 1996; 75:623-6.
- Sastry RC, Lee D, Har-El G. Palatal perforation from cocaine abuse. *Otolaryngol Head Neck Surg* 1997; 116:565-6.
- Sousa O, Rowley S. [Otorhinolaryngologic symptoms caused by the intranasal abuse of cocaine. Report of a case.] *Rev Med Panama* 1994; 19:55-60.
- Schweitzer V. Osteolytic sinusitis and pneumomediastinum: deceptive otolaryngologic complications of cocaine abuse. *Laryngoscope* 1986; 96:206-10.

14. Isner JM, Estes NA 3d, Thompson PD, Castanzo-Nordin MR, Subramanian R, Miller G, and others. Acute cardiac events temporally related to cocaine abuse. *N Engl J Med* 1986; 315:1438-43.
15. Woolverton WL, Johnson KM. Neurobiology of cocaine abuse. *Trends Pharmacol Sci* 1992; 13: 193-200.
16. Das G. Cardiovascular effects of cocaine abuse. *Int J Clin Pharmacol Ther Toxicol* 1993; 31:521-8.
17. Estroff TW, Gold MS. Medical and psychiatric complications of cocaine abuse with possible points of pharmacologic treatment. *Adv Alcohol Subst Abuse* 1985; 5:61-76.
18. Little JW, Falace DA. Dental management of the medically compromised patient. 3rd ed. St. Louis (MO): The C.V. Mosby Co; 1988.
19. Kapila YL, Kashani H. Cocaine-associated rapid gingival recession and dental erosion. A case report. *J Periodontol* 1997; 68:485-8.
20. Parry J, Porter S, Scully C, Flint S, Parry MG. Mucosal lesions due to oral cocaine use. *Br Dent J* 1996; 180:462-4.
21. Rao AN. Brain abscess: a complication of cocaine inhalation. *NY State J Med* 1988; 548-50.
22. Newman NM, DiLoreto DA, Ho JT, Klein JC, Birnbaum NS. Bilateral optic neuropathy and osteolytic sinusitis. Complications of cocaine abuse. *JAMA* 1988; 259:72-4.
23. Sawicka EH, Trosser A. Cerebrospinal fluid rhinorrhoea after cocaine sniffing. *Br Med J (Clin Res Ed)* 1983; 286:1476-7.
24. Meyer R. Nasal septal perforations must and can be closed. *Aesthetic Plast Surg* 1994; 18:345-55.
25. Brown RS, Johnson CD. Corrosion of gold restorations from inhalation of "crack" cocaine. *Gen Dent* 1994; 242-6.
26. Johnson CD, Brown RS. How cocaine abuse affects post-extraction bleeding. *JADA* 1993; 124:60-2.
27. Brown E, Prager J, Lee HY, Ramsey RG. CNS complications of cocaine abuse: prevalence, pathophysiology, and neuroradiology. *AJR Am J Roentgenol* 1992; 159:137-47.
28. Goulet JP, Perusse R, Turcotte JY. Contraindications to vasoconstrictors in dentistry. Part III: Pharmacology interactions. *Oral Surg Oral Med Oral Pathol* 1992; 74:692-7.

Courrier
Suite de la page 194

m'ont dérouté. Le même scénario s'est répété à la Baie verte à Terre-Neuve où j'ai pratiqué dans les années 70.

Dans la Saskatchewan, dans les années 70, les préoccupations et la volonté politique ont incité la formation de dentothérapeutes, assurant ainsi l'accès à des soins dentaires de qualité pour les enfants des régions rurales. À peu près en même temps, un programme similaire a été lancé par le gouvernement fédéral pour former des dentothérapeutes qui travailleraient dans les régions boréales éloignées. Ces auxiliaires dentaires ont cependant été mal reçus par la profession.

D'après mon expérience, la majorité des soins offerts aux personnes confinées à la maison — pour cause d'une maladie chronique, de l'âge, d'un accident ou d'un état de santé débilisant — peuvent être prodigués à domicile par une équipe formée et outillée à cet effet, groupant un dentiste et un dentothérapeute. Je mets ici l'accent sur l'importance d'administrer des traitements là où sont les patients, et ce, autant que possible. Il existe sur le marché des appareils efficaces, très portatifs, dont on pourrait se servir pour traiter les personnes allitées, confinées dans une chaise roulante ou gériatrique, que ce soit dans des établissements de soins prolongés (qui n'ont ni l'espace ni l'argent pour équiper des salles dentaires), des hôpitaux ou des résidences privées.

Notre profession s'attirera beaucoup de bonne volonté si nous pouvons développer les qualités de chef de file et d'innovation nécessaires pour satisfaire aux besoins des personnes confinées à la maison. N'attendons pas que quelqu'un d'autre le fasse!

En mars 1998, une maladie m'a forcé à mettre un terme à mon programme somme toute unique. Je suis confiant que des soins dentaires de qualité — auxquels nous nous attendons tous — seront offerts au moment et à l'endroit requis.

Douglas E. Phillips, DDS, DDPH
Nipawin (Saskatchewan)

INDEX DES ANNONCEURS

| | |
|---|--------------------|
| American Association of Orthodontists | 211 |
| Ash Temple | 186 |
| CDSPI | 197, 224, 228, 239 |
| Colgate | 214 |
| Congrès de l'ADC | 233, 234 |
| Dentsply | 199 |
| Fonds de l'ADC | 226 |
| Fonds dentaire canadien | 232 |
| Ivoclar | 195, 200, 227, 231 |
| Jaguar | 190 |
| Johnson & Johnson | 240 |
| Knoll | 212-3 |
| Nobel Biocare | 188 |
| Oral B | 192 |
| Pharmacia & Upjohn | 206-7 |



Journal
Avril
1999
Vol. 65
N° 4